
Tendon Transfers

Tendon or muscle transfers restore balance to a hand crippled by loss of muscle function. They involve the same basic concept as all reconstructive surgery. Nothing is created; rather, remaining functional parts, or those that can be made functional, are redistributed into the best possible working combination. In the case of paralysis due to severed nerves, their repair usually can restore some useful muscle and sensory function and thus should precede tendon transfers.

Tendon or muscle transfers redistribute power to compensate for power losses due to muscle or tendon destruction or muscle paralysis. They involve detaching the tendon distally, mobilizing the muscle—tendon unit without damage to its neurovascular pedicle and rerouting it to a new distal attachment onto bone or tendon. In no other area of upper limb surgery is a thorough knowledge of functional anatomy more essential, but the procedures are among the most interesting, diversified, challenging, and rewarding. Littler pointed out that the study of functional loss and residual performance of the partially paralyzed hand provides a unique opportunity to gain a real working knowledge of hand dynamics. In the nineteenth century, few tendon transfers were done, but studies late in that century contributed essential background understanding. Notable was the work of Duchenne (1867), who used Faradic muscle stimulation to study the physiology of motion. World War I brought real clinical progress. Classic contributions were made by Jones (1921) in England; Mayer (1916), who at that time was working in Berlin; and Steindler (1918) in the United States. However, it was the surge of interest and concentrated efforts attendant to World War II that produced major advances and led to widespread clinical experience. Stimulation came from the fertile and innovative mind of the indefatigable Bunnell, but refinements were attributable to many others. A landmark paper that continues to be recognized for setting the standards and tone of things to come was that of Littler (1949). Many others have subsequently

added to our current techniques, but there have been few additions to the fundamental concepts set forth in these classic publications.

Occasionally a muscle rather than a tendon may be transferred on an intact neurovascular pedicle to redistribute power. An example is use of the abductor digiti quinti transferred for an opponensplasty. More recently, muscles, usually from one limb to another, have been isolated and transferred with direct neurovascular reconnections at the recipient site to replace critical losses. Obviously, the mechanical scheme for which such transplantations are employed must be direct and simple. When loss of muscle—tendon units is great, the remaining muscle units must be concentrated for movement of the most important joints, whereas joints of less importance are stabilized by arthrodesis.

Basic Principles

The basic principles essential to all successful tendon transfers have been summarized by the author. Tendon transfers involve redistribution, not the creation, of power units. Muscles are transferred from lesser to more important functions so that the overall system is functionally improved. It is like investing money: the amount available at any moment is fixed, but the returns can be enormously different depending on where the assets are invested.

Simplicity in mechanical design favors good results, whereas complexity mitigates against them. In practical terms, this means that the surgeon should select a muscle whose tendon can be surgically rerouted in a straight line between the muscle's origin and the tendon's new insertion. Never should more than one "pulley" for change of direction be introduced. (In fact, sailors know these are not pulleys but fairleads.) Even a single change of direction results in great power loss. If the system functions, it is because of a great excess of power in the transferred muscle relative to that required for the function being restored.

Movements that appear to be simple are in fact complex. They are not the result of a single muscle's contraction but rather the result of the combined and coordinated actions of the prime mover, relaxation of the antagonists, and simultaneous contraction of the stabilizers of all joints traversed by the transferred unit. A basic requirement for effective transfer of power is that every joint between the muscle's origin and its new insertion be stabilized. Otherwise, when the muscle contracts, unstable joints that have been crossed will buckle, expending the amplitude of excursion of the muscle with little or no power being transmitted to the new distal tendon attachment. Normally, a muscle antagonist opposing the protagonist stabilizes each joint. When this normal arrangement is lost and cannot be restored, less important joints must be stabilized by arthrodesis to save the available power units for control of those joints whose mobility is most beneficial.

Tendon transfers after irreparable loss of any one of the three major nerves to the forearm and hand (median, radial, or ulnar) have the potential to result in a functionally good mechanical restoration. Contrary to this, if any two of the three nerves are irreparably lost, a major functional impairment is inevitable, and reconstruction must entail a substantial simplification of the hand's mechanical design if useful function is to be restored. At the same time, wrist extension–flexion, as emphasized by White (1960), is of such fundamental importance that its arthrodesis should be done only as a last resort.

Normal skin sensibility is always desirable, but diminished skin sensibility does not preclude worthwhile improvement from tendon transfers. Even the slightest disturbance of sensibility on the palmar

surfaces will impair ability for small-object precision manipulations such as closing buttons. Whereas perfect sensibility is required for precision manipulations, the other hand functions (pinch, grasp, hook, and stabilizing–holddown activities) can be effectively conducted even with substantial losses of sensibility, provided it is greater than a protective level. In other words, despite the fact that so much has been written on the importance of sensibility, there is in reality no big difference between small and large sensory impairments, as small-object manipulations cannot be done effectively with either. Attempts to grade sensibility are essential for investigative studies of techniques but of little or no value for practical clinical management of patients.

Indications for Tendon Transfers

Neurologic Deficits

The most frequent indication for tendon transfers is paralysis of healthy muscles due to loss of innervation, as illustrated by anterior interosseous nerve palsy (Fig. 20–1). After most nerve injuries, repair will be undertaken, and in favorable cases it can be expected to restore useful levels of muscle power and protective sensibility, though never perfectly. With the very best recovery, the reinnervated muscles tend to exhibit group contraction rather than independent control by individual muscles. For many functions, this group action is completely satisfactory, but for others it is not. In the latter case or if recovery of power is unsatisfactory, tendon transfers should be considered.

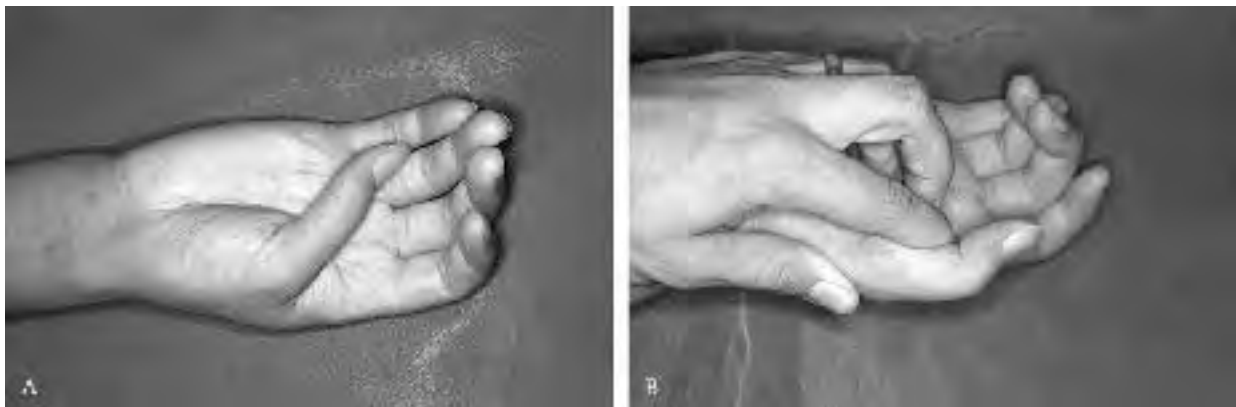

FIGURE 20–1 (A). Loss of thumb interphalangeal (IP) flexion and weak index distal interphalangeal (DIP) flexion due to anterior interosseous nerve palsy. Illustrated is the fact that any muscle can assume a new role completely adverse to its normal role. (B). The extensor indicis proprius (EIP) is so independent that it effectively restores flexor pollicis longus (FPL) function, although normally their functions are in direct opposition. Extensor digitorum profundi of the index and middle fingers have side-to-side transfer to activate the index DIP. This illustrates that the usefulness of the tendon transfer will determine how well it functions, not the issue of synergism.

Tendon transfers usually should be recommended within a few weeks after injury in cases in which the prognosis for neurologic recovery resulting from repair is poor, muscles have been destroyed, or nerve grafts were required to restore nerve continuity. Well-planned tendon transfers are predictable in their restoration of function, so there is no rationale for delaying their utilization in cases with very poor prognosis for nerve regeneration. However, there is great value in the patient's having time to realize fully what he or she has lost and using that as the baseline for judging progress of recovery. There are cases with predictably poor recovery. Others, however, exhibit relatively rapid return of useful function so that tendon transfers occasionally may be done at the time of nerve repair or even without undertaking nerve repair, as with a high radial nerve injury in an older patient with which the nerve repair has little chance of useful recovery. Transfers usually do not prevent functioning of the paralyzed muscles whose function they are augmenting if reinnervation should unexpectedly occur, as in general tendons sutured into the tendon of the paralyzed muscles rather than interrupting their continuity.

Loss of Muscle–Tendon Units Treated by Alternative to Direct Tendon Repair

Tendon transfers may be used for muscles or tendons destroyed by injury or disease (Fig. 20–2). A classic loss is rupture of the extensor pollicis longus (EPL) some weeks after minimally displaced distal radius

fractures. The usual explanation for EPL rupture being associated with minimally rather than grossly displaced distal radius fractures is that, with little or no displacement, there is no disruption of the extensor tendon compartment, so that swelling of the area causes ischemic tendon damage, which does not occur with a ruptured, open sheath. EPL rupture associated with such fractures typically occurs spontaneously several weeks after the fracture was suffered.

Muscles or tendons also can be hopelessly damaged by diseases such as rheumatoid arthritis (Fig. 20–3). If a function that is very important to the patient has been lost, tendon transfer may offer the most direct and reliable method for its restoration. In some cases, the decision is a matter of urgency. If a functionally independent muscle, such as the EPL, is normal but has its tendon disrupted, the surgeon will need to make a choice between efforts to restore continuity to that tendon or to substitute for the whole muscle–tendon unit by a tendon transfer. An independent muscle such as the EPL that has lost its distal attachment will within 7 to 10 days contract, shorten, and lose so much amplitude of excursion as to preclude its reattachment (Fig. 20–4) as well as functionally satisfactory restoration of continuity by a tendon graft. Substitution by a tendon transfer may be the most practical and reliable solution for many situations (see Fig. 20–2).

Transfer of the functionally independent extensor indicis proprius (EIP) to replace the EPL is a very reliable procedure to restore EPL function. The EIP usually is left under the extensor retinaculum, with

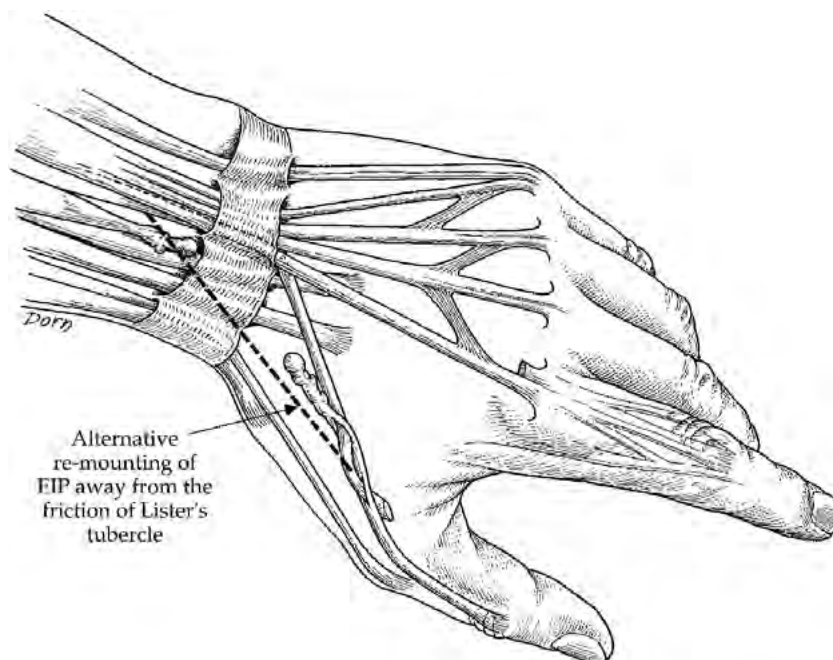


FIGURE 20–2 Plan of EIP to extensor pollicis longus (EPL) transfer. Dotted line indicates alternative subcutaneous rerouting.

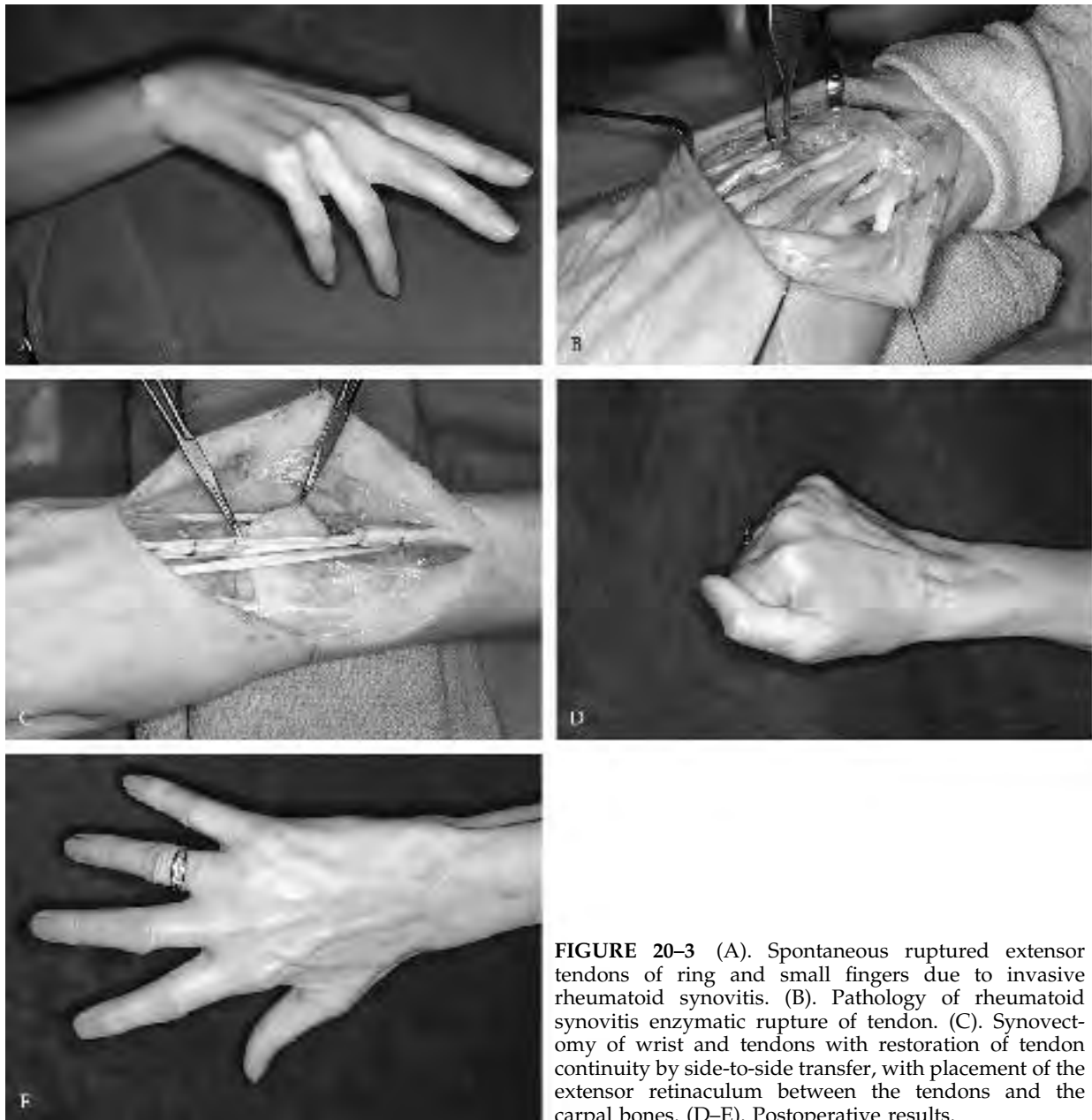

FIGURE 20-3 (A). Spontaneous ruptured extensor tendons of ring and small fingers due to invasive rheumatoid synovitis. (B). Pathology of rheumatoid synovitis enzymatic rupture of tendon. (C). Synovectomy of wrist and tendons with restoration of tendon continuity by side-to-side transfer, with placement of the extensor retinaculum between the tendons and the carpal bones. (D-E). Postoperative results.

the tendon juncture being made distally amid the mobile subcutaneous tissues over the first metacarpal. The EPL tendon can be withdrawn and rerouted subcutaneously if it shows any attrition damage or adhesions at Lister's tubercle. The latter is preferred if rupture has been spontaneous at Lister's tubercle, indicating a pre-disposing disorder. Patients do not notice any loss of the independent index extensor (EIP) after this transfer (see Fig. 20-4). The antagonist to the extensor digitorum communis (EDC), the functionally independent interosseous muscles, can hold the other fingers in flexion, thus allowing the index finger independent exten-

sion via its slip of the EDC. This is another example of apparently simple movements being the result of complex interaction of prime mover, antagonist, and stabilizers.

Another indication for tendon transfer may be adhesion of a damaged tendon, check-reining movements (Fig. 20-5). A tendon repair bypassing a scarred bed of injury has a good prognosis, whereas attempts to repair tendons in a bed of scar, even with early motion, have no chance of success.

Treating spastic disorders may incorporate tendon transfers with other procedures such as tenotomy or arthrodesis in a cautious manner, but conservatism is

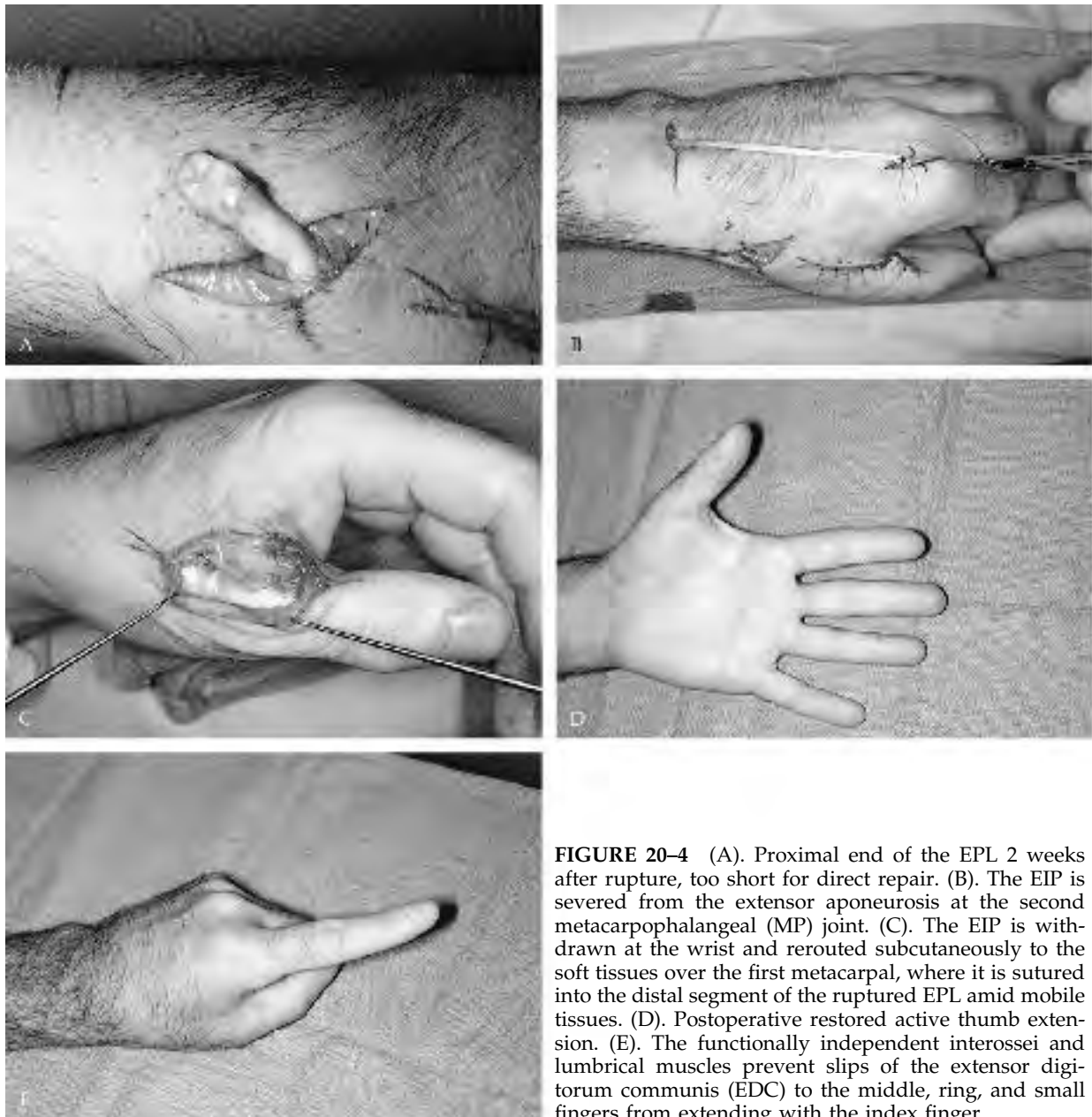

FIGURE 20-4 (A). Proximal end of the EPL 2 weeks after rupture, too short for direct repair. (B). The EIP is severed from the extensor aponeurosis at the second metacarpophalangeal (MP) joint. (C). The EIP is withdrawn at the wrist and rerouted subcutaneously to the soft tissues over the first metacarpal, where it is sutured into the distal segment of the ruptured EPL amid mobile tissues. (D). Postoperative restored active thumb extension. (E). The functionally independent interossei and lumbrical muscles prevent slips of the extensor digitorum communis (EDC) to the middle, ring, and small fingers from extending with the index finger.

strongly indicated, as it is very difficult to treat by peripheral procedures a problem that lies basically in the central nervous system.

Evaluation and Establishment of Goals

History

Evaluation should begin with the taking of a detailed history. If an injury has occurred, as much as possible should be learned about the mechanism of that injury. This not only provides important information, such as progressive disease or pertinent concomitant pro-

blems, but also guides further investigation. Also, during this step much can be learned about the patient (e.g., the patient's intellectual capacity, expectations, and motivation). To the patient, these efforts on the part of the surgeon are an expression of interest that goes far in establishing good rapport and a trusting relationship from the outset.

Task Analysis and Establishment of Goals

Of course, every patient wants his or her hands returned to a fully normal state, but often this is not possible. It is absolutely essential that the baseline for

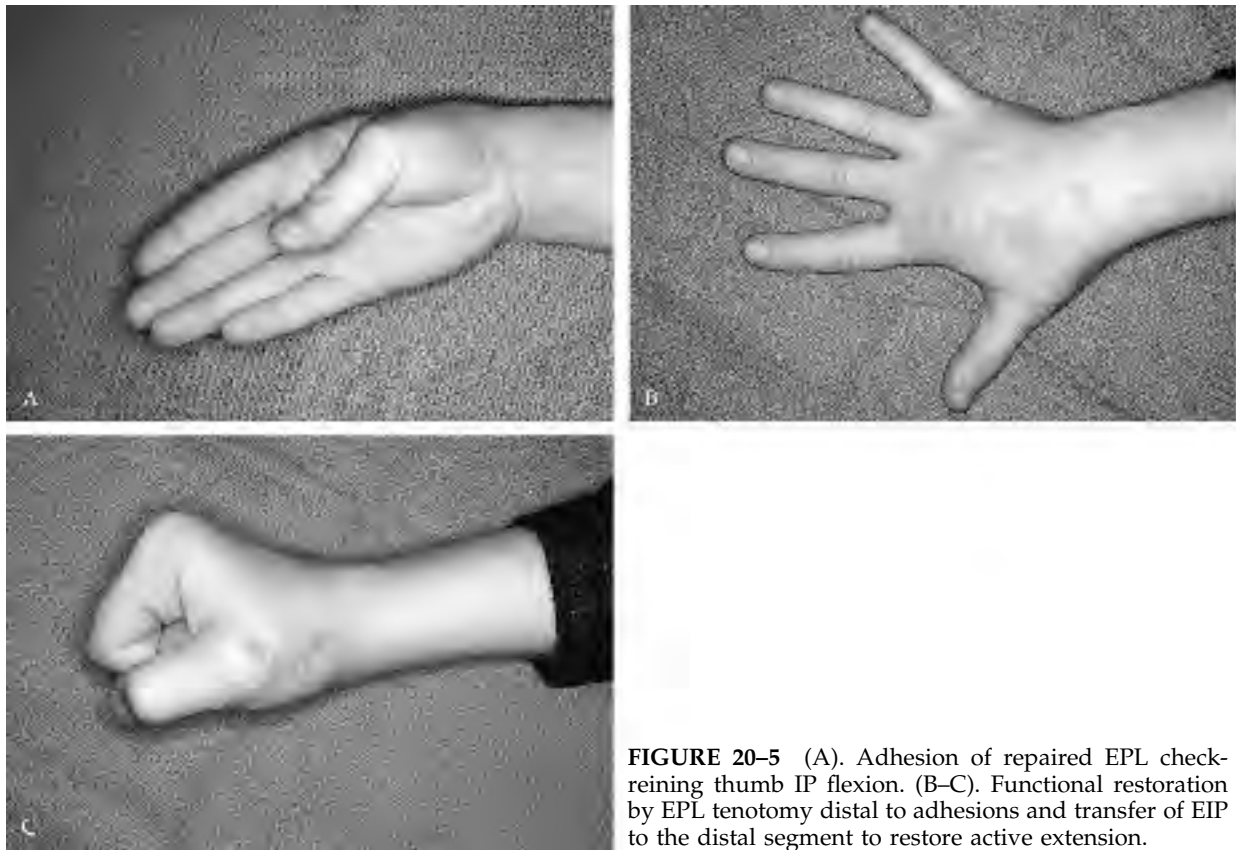


FIGURE 20-5 (A). Adhesion of repaired EPL check-reinforcing thumb IP flexion. (B–C). Functional restoration by EPL tenotomy distal to adhesions and transfer of EIP to the distal segment to restore active extension.

judging improvement be the hand following injury and not the normal hand. Therefore, the surgeon must inquire and interpret carefully all observations and information from the patient, establishing the patient's real yet obtainable needs and guiding his or her expectations. No time is better spent than sorting out and ranking in order of priority the patient's paramount needs and desires. The key to a successful operative plan is first to define realistic and specific goals. Once these are agreed upon, the chances of accomplishing them to the patient's satisfaction usually will be good. This reinforces the idea that the baseline against which progress must be judged is the condition of the hand prior to treatment rather than the normal hand. Using this realistic baseline helps both the patient and the surgeon realize that good progress is being made and helps to stave off an unwarranted sense of disappointment that most certainly will develop if the normal part is used for reference.

Sometimes it is possible to test a planned scheme with splints and orthotic devices, eventually doing surgically under the skin what the external testing devices have shown to be beneficial. A tenodesis wrist-driven splint for a C5–C6 tetraplegic patient is a good example of this.

Motivation

High motivation and realistic expectations are important for good results from tendon transfers. Patients who show little interest in their problem or maintain unrealistic expectations are poor candidates for surgical repairs. Tendon transfers are not just to restore motion. They are to concentrate available power units into the best working combination to reduce functional impairment and to meet specific functional needs. Restoring badly impaired hands to normal is the exception, so keeping expectations realistic is most important.

Prerequisites to Tendon Transfer Surgery

Open Wounds

A patient is not a candidate for a tendon transfer if he or she has open wounds that could predispose to a disastrous postoperative infection. Also, there may be tissue losses, in which case replacement may be essential to wound closure, provided there are mobile subcutaneous tissues along the route of the envisioned transfer.

Soft Tissue Coverage

Tendon transfers will glide only if transplanted through mobile, unscarred, healthy tissues. Meeting this requirement usually entails subcutaneous rerouting of the tendon out of contact with scar and fixed structures. If tissue replacement is required, it generally entails a flap to provide both skin and subcutaneous tissues. It should be completed and thoroughly healed before any tendon transfers are undertaken.

Maximum Joint Mobilization Established

One never gains more active range of motion from tendon transfers than the preoperative passive range of motion. Therefore, it is important that good joint mobility precede tendon transfers. With disrupted motor nerves or muscle–tendon losses, the imbalance of forces acting across the joints occurs immediately (with the exception of total paralysis, in which there is no imbalance). In contrast, joint stiffening and deformity develop as the result of the imbalance. Attention to joint stiffening and deformity with appropriate therapy and splinting can substantially prevent these complications.

Skeletal Stabilization

Joints normally are stabilized by the simultaneous contraction of their protagonist and antagonist, or isometric contractions. If insufficient functioning muscles exist to provide this, joints whose mobility is of lesser importance must be stabilized by arthrodesis. When skeletal stabilization requires arthrodesis, it generally should be achieved prior to tendon transfers. An exception may be a plan in which a wrist fusion is required, because observations of the tenodesis effect from wrist flexion–extension are helpful in judging the tension of the tendon transfers and, postoperatively, wrist mobility is helpful in gliding of the transferred tendons.

Restored Sensibility

When possible, restoration of at least protective sensibility should precede tendon transfers. As previously emphasized, skin sensibility is not absolutely required for tendon transfers to be useful, but it is always desirable. Sometimes restoring precision sensibility on a limited but critical surface, such as the pad of the thumb's distal phalanx, by neurovascular sensory island transfer may be an important adjunct to power redistribution. Again, if skin sensibility is not absolutely normal, there is no great difference clinically between slightly and substantially diminished sensibility, as both preclude effective precision manipulations. Consider patients with only mild

symptoms of carpal tunnel syndrome and the difficulty they have even closing buttons.

Selection of Muscles for Transfer

Availability

Having established the functional needs and goals for a patient who is an emotionally suitable candidate for tendon transfer, the next step is to develop the plan that will best meet his or her needs. This is initiated by making a detailed inventory of the existing assets, grading and recording the power of each muscle in the limb. A 0 to 5 scale is employed:

- 0 muscle shows no active movement
- 1 muscle can move against gravity only
- 2 muscle is too weak for a basic task
- 3 muscle is weak but has some useful power
- 4 muscle is weak but has near-normal power
- 5 muscle is fully normal

Of course, the muscle selected for transfer must be a greater contributor in its new role than in its normal function.

Power and Control

To be a candidate for tendon transfer, a muscle must have adequate power for the new function, be nonspastic, and be under good volitional control. It also needs to be an independently functioning muscle unit, such as a finger superficial flexor or the EIP, in contrast to the flexor digitorum communis (FDC), whose four tendons originate from a common muscle. In general, only muscles having a power grade of 4 or 5 (on the 0 to 5 scale) are suitable candidates for transfer.

Amplitude of Excursion

The muscle to be transferred must have an adequate amplitude of excursion for its new function or be so situated that its effective amplitude can be enhanced by tenodesis as it crosses an actively controlled joint. Most often this joint will be the wrist. If a wrist extensor having less amplitude of excursion than the flexor digitorum profundus (FDP) is used for finger flexion, full finger extension is achieved by simultaneously flexing the wrist as the fingers are extended. This enhances the "effective" amplitude of excursion of the transferred wrist extensor by tenodesis. The opposite is achieved by wrist extension as the fingers grasp.

Anatomic Location

To be considered for transfer, a muscle must be so located that its transfer is anatomically and

mechanically feasible. The surgical rerouting of a muscle and tendon should be in as direct a line of pull as possible between the muscle's origin and its new insertion. Otherwise, as it begins to function, it will work into a straight line of pull and become too slack. Never can more than one change of direction be workable. Simplicity of design favors good results.

Synergism

Muscles that simultaneously and automatically contract to work together are referred to as synergistic. An example is wrist extension with finger flexion, as has already been discussed. Synergism was once considered important in selecting muscles for transfer, but it is much less important today (Fig. 20-1). The way the muscle control system works is that any muscle can participate in any activity, and the ease with which it does so is basically a factor of how useful that activity is rather than the normal functions of the muscle.

Expendability

Obviously, if a muscle is to be transferred for a new duty, the surgeon must be certain that this will be of more benefit to the patient than the muscle is in its normal situation.

Potential PIP Joint Complications

The surgeon should be constantly aware of the possibilities of creating secondary problems. If the proximal interphalangeal (PIP) joint of the finger from which the flexor digitorum superficialis (FDS) is to be taken is hyperextensible from an incompetent or ruptured volar plate, taking its FDS tendon can cause a distressing recurvatum deformity. If the hyperextensibility is slight, simply leaving one slip of the FDS long so it can adhere proximally in the tendon sheath is all that is necessary. However, with gross hyperextensibility of the PIP joint, suturing a long distally attached slip of the FDS to its proximal sheath is necessary for tenodesis control of the joint.

Another consideration is the possibility of excessive power as a result of a tendon transfer. For example, if the PIP joint is supple and hyperextendable, in contrast to the consistent fixed flexion contractures of leper patients, putting a tendon transfer into the lateral bands to restore metacarpophalangeal (MP) flexion can result in an imbalance toward PIP extension, with development of a very troublesome PIP recurvatum deformity.

Relation of Muscle Excursion to Power Output

Muscle amplitude of excursion has a relation to power output as well as range of motion, which is illustrated by my modification of the Blix curve (Fig. 20-6). A muscle is capable of maximum power

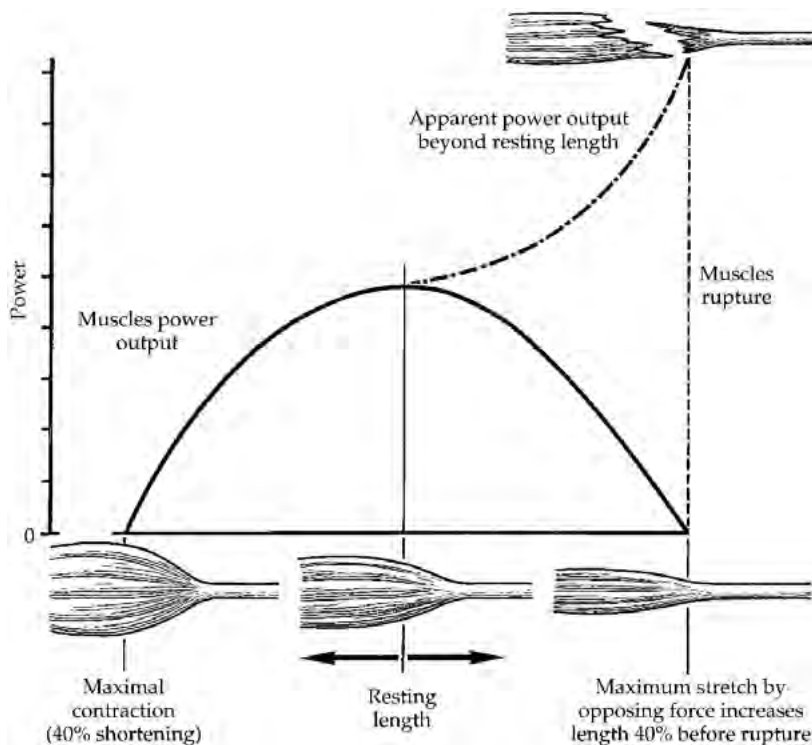


FIGURE 20-6 Modification of the classic Blix curve to reflect what is actually observed: increasing power with stretch beyond the resting length at which muscle power output is maximal. The apparent increase in power is equal only to the energy input for the stretching. Power output of a muscle declines with either redundancy or stretching from its resting point.

production at its resting length. A muscle can shorten from its resting length about 40% by contracting; at that point, further power output ceases. A muscle also can be stretched about 40% from its resting length before it is ruptured. The energy required to stretch the muscle is stored and can be recovered, as illustrated by the Blix curve. This does not tell the whole story, however, because the power available from a contracting muscle is diminished progressively by the amount of energy used to stretch the antagonist. The result is that measured power increases with stretching to the point of muscle rupture, but not linearly. The curve flattens progressively, as the contribution of the muscle's power output decreases and power is increasingly used to overcome progressive resistance of stretching the antagonist. Highly efficient output of power by the muscle itself is over a remarkably narrow range, a centimeter or so for most muscles on each side of its resting length.

In the normal limb wrist, flexion and extension are important not only for strategic positioning of the hand but also for modulating the tension of the finger flexor muscles to keep their length optimal for power output, as determined by the size of the object being grasped or pinched. When pinching a large object, the wrist flexes, which effectively lengthens, by tenodesis, the finger flexors to keep them in the range of maximum power production. When pinching a small object, the wrist synergistically extends to take "slack" out of the finger flexors to maintain their tension in the narrow range of optimal power output.

Adjustment of Tension for Tendon Transfers

At the time of the operation, the muscle can be passively stretched to determine the possible extent of its stretch without rupturing, which also reflects

approximately the distance it can contract from its resting point. Such observations have limited practical application, however, and careful observation of the tenodesis effect is much more helpful. With tendon transfers, the tension is set tentatively by a single trial suture, after which the movement of the parts resulting from the tenodesis effect from passive movements is carefully observed. Tension adjustments are then made accordingly before the final secure suturing is completed (Fig. 20-7).

Tendon Transfers for Muscle-Tendon Unit Destruction

For many circumstances with which there are functional problems due to direct muscle or tendon loss, a tendon transfer will be more suitable to restore specific function than attempting to repair the normal system. This is especially true when the tendon has ruptured because it is damaged by disease such as rheumatoid arthritis (see Fig. 20-3). A highly predictable tendon transfer may be selectively employed rather than undertaking a less predictable repair of a structure. A typical example is attritional rupture of the EPL at Lister's tubercle.

Tendon Transfers for Specific Palsies

The variety of disorders encountered is endless, so management must be with thoughtful application of principles individualized to the circumstances of each situation. Examples presented here are given to illustrate the principles, with no attempt made to mention all of the possibilities that might be employed with good results. In general, few patients with spastic paralysis are candidates for tendon transfers. The spastic patients fall into two groups: for the majority, surgery will be considered to

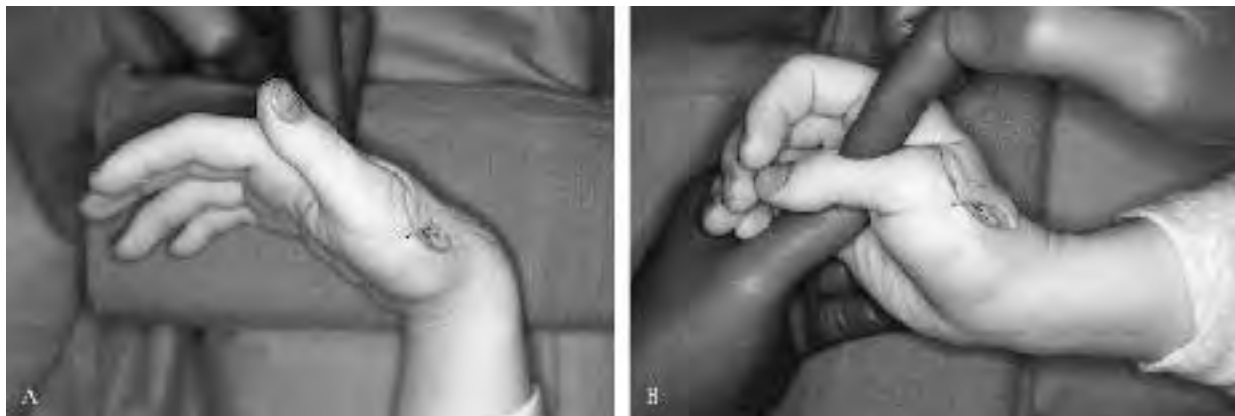

FIGURE 20-7 Tenodesis effect observed with wrist extension or flexion is most helpful for accurate adjustment of the tension of tendon transfers. (A). Illustrated is full thumb extension caused by wrist flexion. (B). Passive adduction of the thumb to the third metacarpal with full wrist extension following transfer of the flexor carpi ulnaris (FCU) into the combined EDC and EPL.

simplify care, improve hygiene, or better social presentation; for a very small second group, the goals are to improve physical capability.

Radial Nerve Palsies

Radial nerve palsies are divided into low or high lesions. The losses of low radial nerve lesions are those of a posterior interosseous palsy. The need is for active MP finger extension, thumb extension (retropulsion), and, very rarely, thumb abduction. If nerve injury has been in the midforearm, the extensor carpi ulnaris (ECU) may be spared paralysis, as it is innervated in the proximal forearm. Active wrist extension is not lost with low radial nerve lesions, as nerves to the extensor carpi radialis longus (ECRL) and extensor carpi radialis brevis (ECRB) separate from the main trunk of the radial nerve proximal to the elbow and are not injured with more distal lesions of the posterior-interosseous division of the radial nerve. With both median and ulnar nerves functioning, the intrinsic muscles will provide active IP finger extension. A high radial palsy presents the same clinical picture as a low one, except that with the high lesion, there is complete loss of active wrist extension.

Fortunately, loss of skin sensibility from disruption of the superficial branch of the radial nerve is to the dorsal surface of the hand and not to a functionally critical surface. The problems of injury to the superficial division of the radial nerve are those of pain, neuromas, and skin dysesthesia (see Chapter 23).

LOW RADIAL NERVE PALSIES

My choice for transfer schemes for low radial palsy is the flexor carpi ulnaris (FCU) brought subcutaneously around the medial side of the forearm and sutured into the combined EDC, EIP, and eventually EPL (Fig. 20-8). First, the multiple slips of the EDC and the EIP are sutured together so that passive pull extends all MP finger joints equally. The EDC slip to the small finger varies greatly. If pull on the EDC results in inadequate extension of the fifth MP joint, the extensor digiti minimi (EDM) tendon should then be included in the transfer but not routinely, as its inclusion causes an undesirable degree of abduction of the small finger.

The muscles of the paralyzed digital extensors extend so far distally that the transfer junctures will be very near or in contact with the dorsal retinacular ligament. Usually the proximal portion of this fixed retinacular structure should be excised to prevent the tendon junctures of transfer from adhering to it. Tension of the tendon transfer is adjusted by observing the tenodesis effect of passive wrist flexion-extension on the MP finger joints. They should be hyperextended by full wrist flexion, and the patient

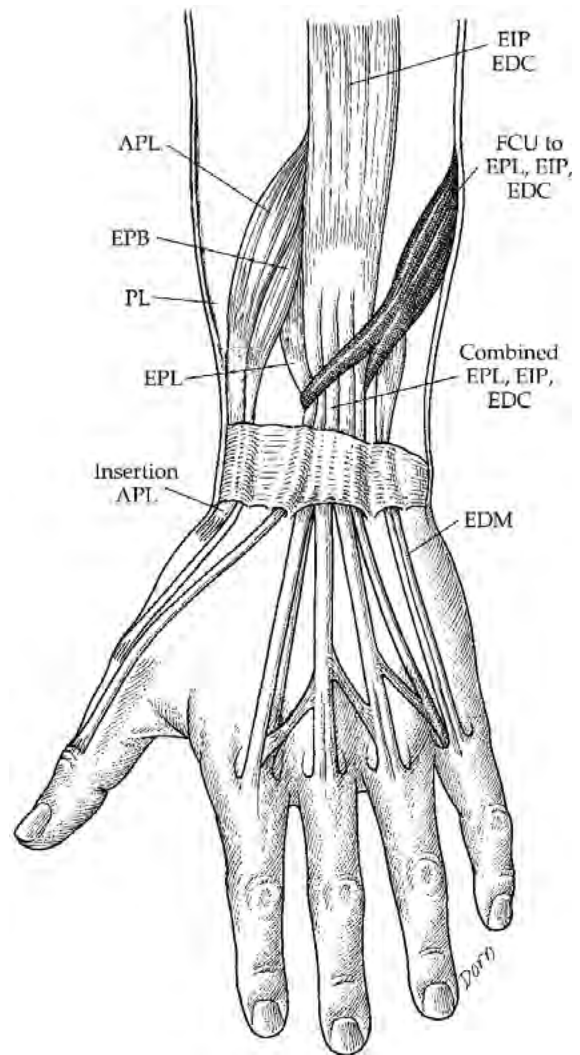


FIGURE 20-8 Low radial palsy is best treated in most cases by subcutaneous transfer of the FCU around the medial side of the forearm and inserted into the combined EDC, EIP, and eventually EPL. The extensor digiti minimi (EDM) is included only if there is no EDC slip to the small finger because it causes prominent abduction of the small finger.

should be able to bring the fingertips to within about 3 to 4 cm of the distal palmar crease when the wrist is fully hyperextended.

Once the juncture with the finger extensors is completed, the EPL is added into the group so that the FCU transmits power to it also. Only by separation of these units can tenodesis be used effectively for adjustment of tension for each. The EPL can be displaced subcutaneously from the third extensor compartment for a more direct line of pull and to avoid the friction of change of direction around Lister's tubercle. A trial suture is first placed, and tension is evaluated again by observing the thumb movement from the wrist tenodesis effect. It is

adjusted as necessary before final secure suturing is done. Tension on the EPL should be such that the thumb is hyperextended with full wrist passive flexion, but its tip can easily be brought across the palm to about the third metacarpal head when the wrist is hyperextended. This simple one-muscle scheme of transfer for low radial palsies provides excellent functional restoration because the normal median and ulnar innervated antagonist muscles prevent unwanted motion of the thumb and fingers from the combined unit that is created (Fig. 20-9). Wrist ulnar deviation is not lost because the FCU is brought around the medial side of the wrist en route to insertion into the digital extensor tendons. The flexor carpi radialis is centrally located, and thus the prime wrist flexor opposing the ECRB, and should not be used in the treatment of radial nerve palsy.

For isolated low radial palsy, transfer of the FCU into the combined EDC, EIP, and EPL functions superbly and is favored, but it is certainly not the only option and for various reasons may not always be feasible. A little known plan I have found to be very successful is transfer of the pronator teres (PT) into the combined EDC, EIP, and EPL. Pronation of the forearm is not compromised, as the finger flexors can block finger extension, which fixes the point of PT

insertion almost directly over its normal insertion into the radius.

Another alternative is transfer of one or two finger superficial flexors through a large window created in the interosseous membrane for insertion into the digital extensors. Alternatively, the tendon can be rerouted subcutaneously around the forearm.

In the past, tendon transfer schemes tended to be more complex, using more muscle-tendon units than are utilized today. One option is to repower the abductor pollicis longus (APL), usually by transfer of the palmaris longus into it. Theoretically, this provides a more normal restoration, but it is not needed, as patients never miss APL functional loss. Another option is to transfer the palmaris longus into the EPL, but the FCU combined single unit transfer to fingers and thumb works so well that there are few if any indications for the additional surgery of transferring the PL to the EPL or APL. The flexor carpi radialis (FCR) rather than the FCU should not be electively used for transfer for combined thumb-finger extension as was advocated during the period of ultracomplex transfer schemes that followed World War I. The FCU is better located anatomically for transfer and also is more expendable. The FCR is the prime wrist flexor. Its insertion is central, opposing and balancing the prime wrist

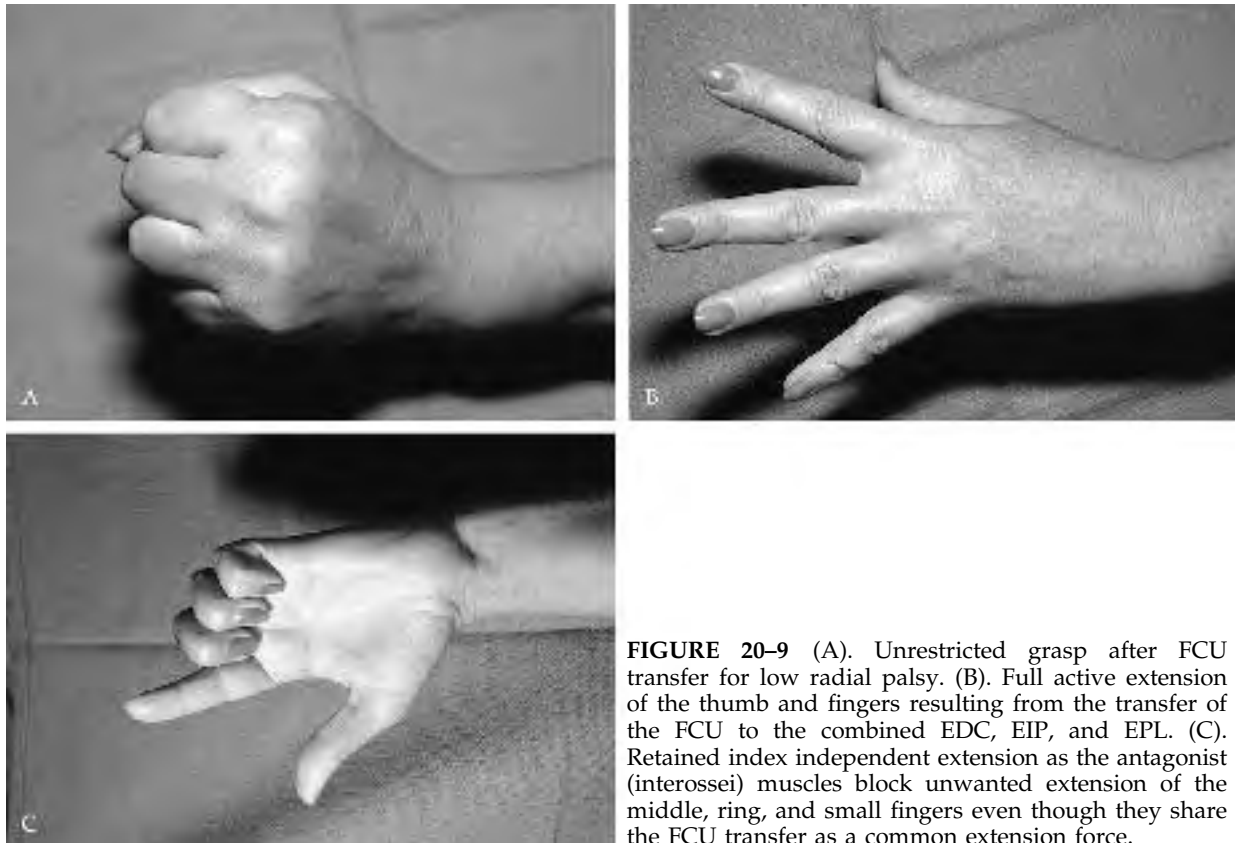


FIGURE 20-9 (A). Unrestricted grasp after FCU transfer for low radial palsy. (B). Full active extension of the thumb and fingers resulting from the transfer of the FCU to the combined EDC, EIP, and EPL. (C). Retained index independent extension as the antagonist (interossei) muscles block unwanted extension of the middle, ring, and small fingers even though they share the FCU transfer as a common extension force.

extensor, the ECRB, and causes minimal deviations of the wrist.

Postoperative immobilization is for 3 weeks, with wrist hyperextension and the thumb and fingers in moderate flexion, a relaxed position but with full flexion being blocked. After 3 weeks of immobilization, free thumb and finger movements, without forceful grasping, can be allowed, while hyperextension of the wrist is continued an additional 3 weeks. With the wrist hyperextended, the antagonists to digital extensors, the powerful digital flexors, cannot put much force on the tendon junctures. Unrestricted use is not encouraged until 8 weeks following transfers. In the case of children, full immobilization may be required for 6 more weeks.

HIGH RADIAL PALSIES

High radial nerve lesions result in a total loss of wrist extension due to paralysis of the ECRB, the ECRL, and the posterior interosseous innervated ECU but a superb functional restoration is possible (Fig. 20-10). It requires only two muscle transfers, the PT to the ECRB and the FCU or other muscle to the combined thumb and finger extensors. The ECRB has the best mechanical advantage for wrist extension, as its insertion is the most dorsal from the flexion-extension axis of rotation of the wrist joint. Considering this, restoration of active wrist extension is by tendon transfer into the tendon of the ECRB, not the ECRL. This transfer works well and is the best choice for restoring wrist extension unless the PT is available. The PT is well situated anatomically for a direct line of pull without rerouting. It has adequate power and excursion. Because its insertion into the ECRB is directly over its normal attachment into the radius, it continues to function as an effective forearm pronator. It also is less of a wrist deviator than the ECRL.

When tendon transfers are for high radial nerve palsy, it is important that the transfer to restore active extension to the thumb and fingers precede the transfer for wrist extension. This permits the tenodesis effect of the wrist movements to be used to adjust the tension of the transfers. Transfer of the PT into the ECRB is with the forearm pronated and the paralyzed ECRB pulled medially into the anterior forearm as far as possible. The objective is to have as straight a line of pull as possible between the PT's origin from the medial epicondyle of the humerus to the normal insertion of the ECRB. Regardless of these efforts, some further postoperative rerouting and loosening of the transfer always occur. Therefore, the surgeon cannot set the tension of the transfer of the PT into the ECRB to restore wrist extension too tightly, so long as the sutures do not pull through. Of course, postoperative immobiliza-

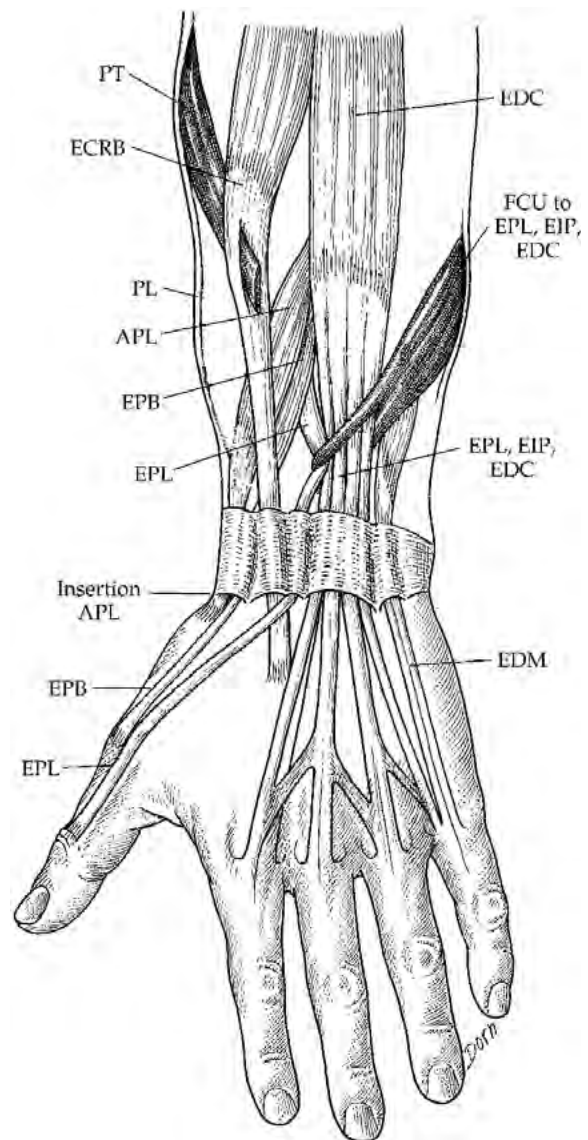


FIGURE 20-10 With high radial palsy, transfer of the pronator teres (PT) into the extensor carpi radialis brevis (ECRB) is the best choice for restoring an active wrist. The prime function of the PT is not lost. The biceps muscle (a powerful supinator) relaxes, and the finger flexors tighten; this fixes the point of the transfer's junction over the site of normal PT insertion into the radius. Restoration of normal thumb and finger extension is the same as with low radial palsy.

tion is with maximum wrist extension while maintaining forearm pronation. Wrist hyperextension must be maintained for 6 weeks, but unresisted thumb and finger exercises are encouraged after 3 weeks (Fig. 20-11).

Frequently the fibrous margin (tendon) of the PT is thin and fragile. The juncture between the PT and the ECRB can be greatly strengthened by a slip of the broad ECRB tendon left attached distally but cut free proximally from its paralyzed muscle and rotated

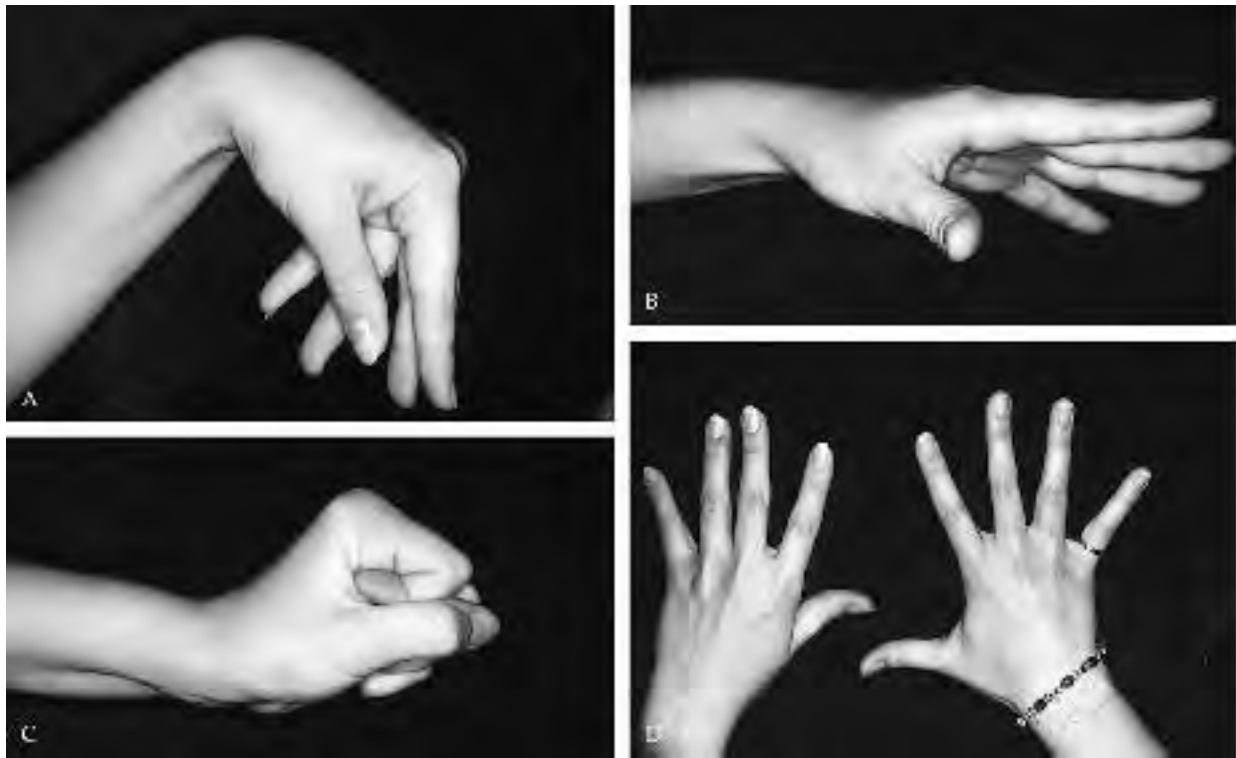


FIGURE 20-11 (A). Classic deformity of high radial nerve palsy with complete loss of wrist and finger MP extension. IP extension is provided by the intrinsic muscles. (B). Digital extension is restored by transfer of the FCU to the combined EDC, EIP, and EPL. (C). Active and independent wrist extension is restored by transfer of the PT into the ECRB, the prime wrist extensor. (D). The comparable photographs of left and right hands show a slight reduction of thumb abduction following the recommended transfers.

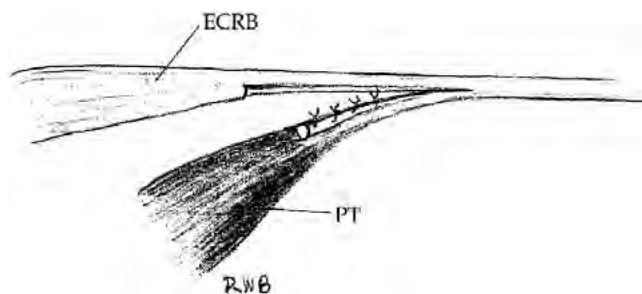


FIGURE 20-12 If the tendon and periosteum of the detached PT are very thin and thus not fully suitable for a strong juncture with the ECRB, the juncture can be reinforced by a distally based slip of the ECRB tendon.

anteriorly to be securely sutured along the PT margin (Fig. 20-12).

An alternative is to use one or more digital superficial flexor muscles (FDS), for example, the FDS III for finger MP extension and the smaller FDS IV for the EPL (Fig. 20-13). The FDS muscles obviously are not synergistic transfers for restoring digital extension, but they can work well because of their almost complete functional independence. FDS transfers can be routed subcutaneously around the ulna, or they can be brought through the interosseous

membrane for a more direct line of pull (Fig. 20-14). If the latter route is chosen, the muscle proper, not just the tendon, must be brought through a large fenestration created in the interosseous membrane. If the tendons alone are brought through the interosseous membrane, invariably they will become bound by adhesions to the fixed membrane, and the procedure will be a failure. This is a frequent complication even when the muscle has been brought through the membrane.

Ulnar Palsies

Ulnar innervated muscle losses are much more complex than those of the median or radial nerves. Ulnar nerve lesions may be either high (proximal to the wrist) or low (at the wrist level). The ulnar innervated intrinsic muscles within the hand are characterized by a high degree of independent function of each and thus are essential for control of refined movements. These independent capabilities cannot be fully restored. The best that can be offered is substitution for the major muscle group actions, namely, MP finger joint flexion and thumb adduction power. Both thumb and finger function are profoundly affected by ulnar nerve paralysis, and there is

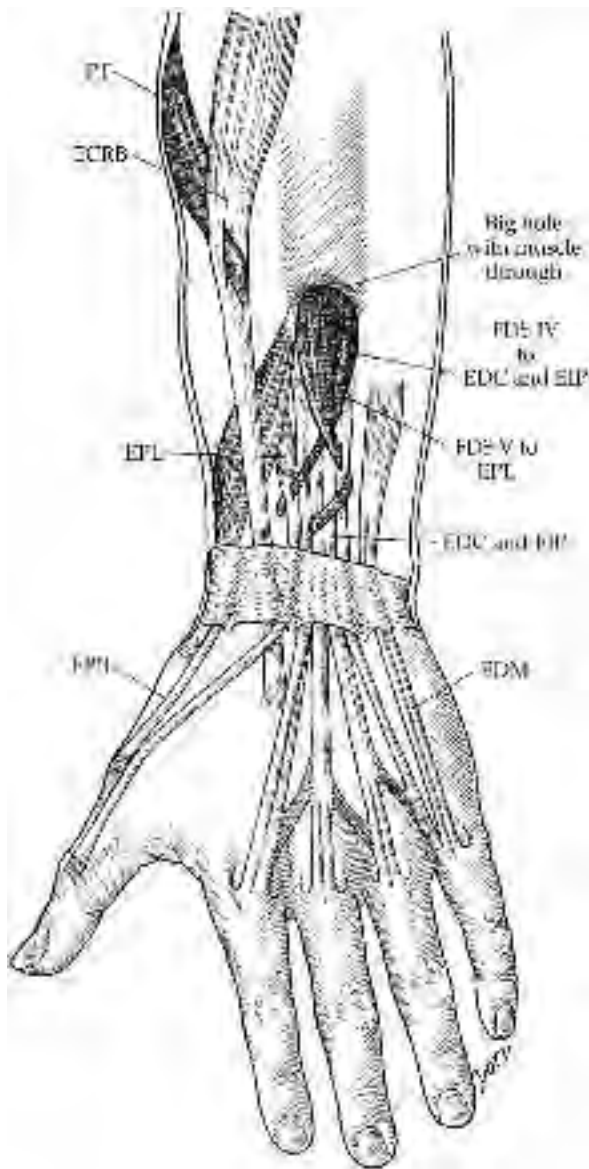


FIGURE 20-13 Digital extension can be restored with one or two flexor digitorum superficialis (FDS) muscles brought through the interosseous membrane to the dorsal forearm's fourth extensor compartment. The muscles must be brought through a large fenestration in the membrane, or tendons will consistently become adherent there. The palmaris longus can be transferred to the abductor pollicis longus, but this is rarely if ever required.

the potential for improvement but not full restoration of their complex functions.

LOW ULNAR PALSIES

With low ulnar palsy, treatment is directed to two basic needs: obviating the "claw" deformity of the ring and small fingers and augmenting thumb adduction power for an effective lateral pinch.

The "Claw" Deformity. Ulnar palsy causes all interosseous muscles as well as the lumbricals to the ring and small fingers to be paralyzed. Whereas the median innervated lumbricals to the index and middle fingers flex their MP joints and prevent the claw deformity, the ring and small fingers with ulnar palsy have only ulnar innervated MP joint flexors. With the median innervated superficial digital flexors intact, the compressive forces on the multiarticulated ring and small fingers add to their MP imbalance toward extension, and a progressive claw deformity (MP hyperextension with reciprocal PIP acute flexion) develops (Fig. 20-15). Imbalance immediately follows loss of innervation, but deformity develops. Appropriate splinting usually can prevent its becoming a fixed deformity.

Normal independent adduction and abduction, which are necessary for refined finger movements, cannot be restored. The best that can be done is to control "clawing" by blocking MP joint hyperextension (Fig. 20-16), but restoring active flexion to the MP joints is obviously more physiologic. Tenodesis or dermatodesis to prevent MP hyperextension stretch out. With inadequate muscles for transfer, MP arthrodesis through a palmar approach effectively prevents finger clawing (Fig. 20-17).

Low ulnar nerve palsy produces a classic thumb deformity, referred to as Froment's sign (Fig. 20-18). This is a hyperextension of the thumb's MP joint due to loss or weakness of the ulnar innervated intrinsic muscles that normally flex its MP joint. As the MP joint collapses in hyperextension, the IP thumb joint is flexed maximally by the median innervated FPL in an effort to compensate for the power loss due to MP instability. Thumb adduction weakness always occurs with ulnar nerve lesions due to paralysis of the adductor pollicis, the first dorsal interosseous muscle, and a variable degree of weakness of the deep head of the flexor pollicis brevis (FPB) as determined by the proportion of the latter innervated by the median or the ulnar nerve (see Chapter 2, Fig. 2-20). Another variable is the adduction contribution from the EPL, whose line of pull makes it a contributor to thumb adduction. Thus, about 35% of patients with complete ulnar nerve palsy exhibit enough thumb adduction or lateral pinch weakness to need power augmentation with a tendon transfer.

Correction of the two basic deformities of ulnar nerve paralysis is combined into one operation. A typical plan is illustrated in Figure 20-19.

Usually the best approach to correct clawing is to use a digital superficial flexor divided distally into two slips, one for the ring and one for the small finger. Each tendon slip is passed anterior to the intercapsular (intermetacarpal) ligaments to be palmar to the axis of rotation of the MP joints and thus the flexors.

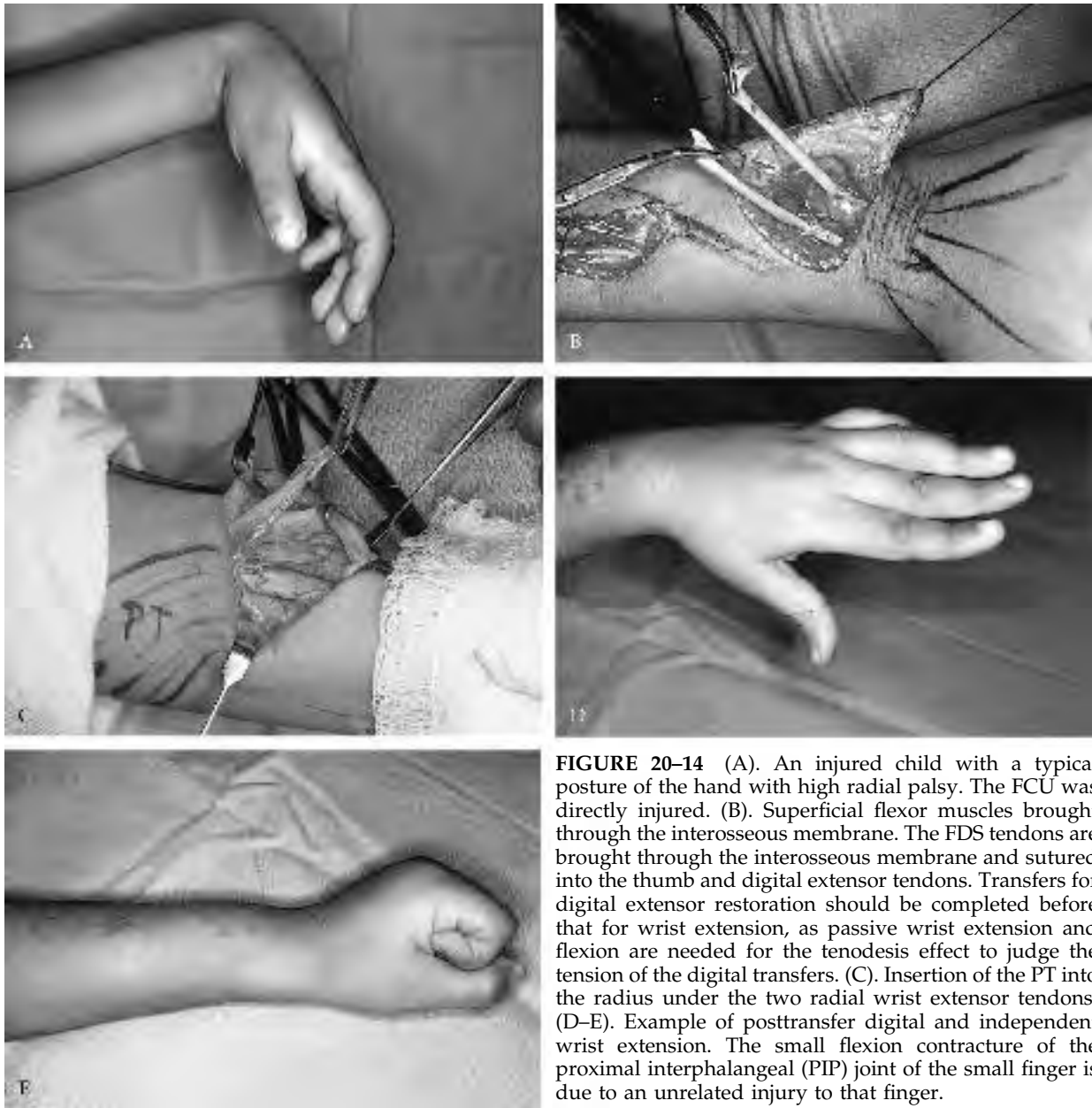

FIGURE 20-14 (A). An injured child with a typical posture of the hand with high radial palsy. The FCU was directly injured. (B). Superficial flexor muscles brought through the interosseous membrane. The FDS tendons are brought through the interosseous membrane and sutured into the thumb and digital extensor tendons. Transfers for digital extensor restoration should be completed before that for wrist extension, as passive wrist extension and flexion are needed for the tenodesis effect to judge the tension of the digital transfers. (C). Insertion of the PT into the radius under the two radial wrist extensor tendons. (D-E). Example of posttransfer digital and independent wrist extension. The small flexion contracture of the proximal interphalangeal (PIP) joint of the small finger is due to an unrelated injury to that finger.

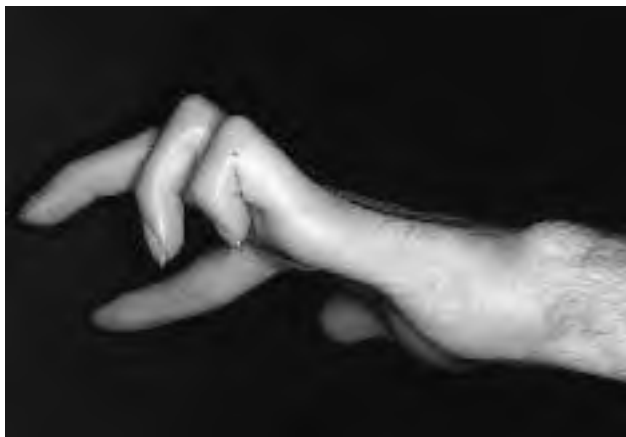

FIGURE 20-15 Example of classic ulnar palsy with interosseous muscle atrophy, with "claw" deformity of the ring and small fingers and atrophy of the thumb adductors.

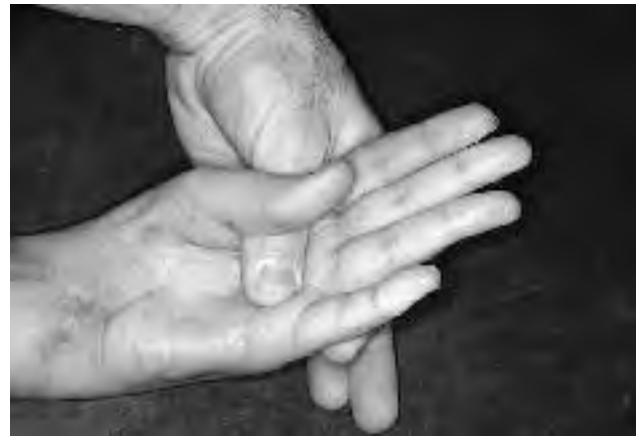

FIGURE 20-16 If MP joint hyperextension is blocked, radial innervated muscles provide full active PIP extension through the extensor's central slips.

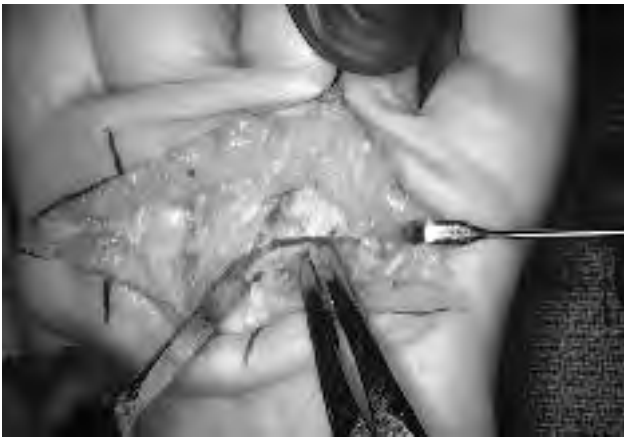

FIGURE 20-17 With insufficient functioning muscles for transfer, MP joints can be fused in flexion through a palmar approach without damage to the extensor aponeurosis.

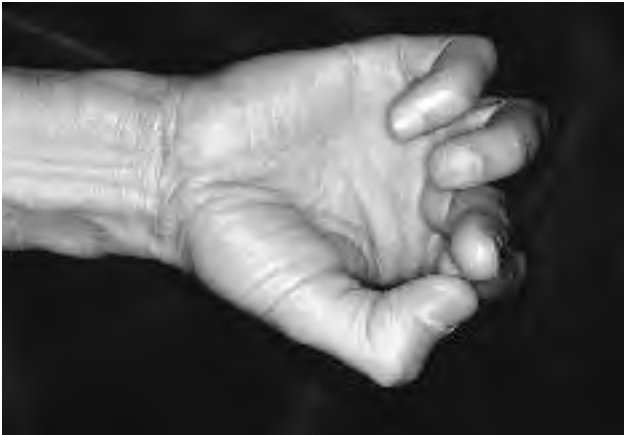

FIGURE 20-18 Froment's sign of ulnar palsy results from a loss of flexion and stability of the thumb's MP joint, accompanied by an ineffectual attempt to compensate by interphalangeal hyperflexion by the FPL.

Three types of tendon insertion are possible. First, the tendon can be put into the bone at the base of the proximal phalanx, but technically this is difficult. Second, the transfer can be woven into the lateral band (tendon of the interosseous muscle) in a manner mimicking the normal anatomic arrangement, but very often it is too powerful and overloads the IP extensor mechanism, causing a PIP recurvatum or "swan neck" deformity. This insertion should be considered only if the PIP joints have established flexion contractures. If long-standing severe PIP flexion contractures have attenuated the central slip of the extensor system, the tendon transfer can be carried across the PIP joint and sutured into the lateral band on the opposite side at the base of the middle phalanx.

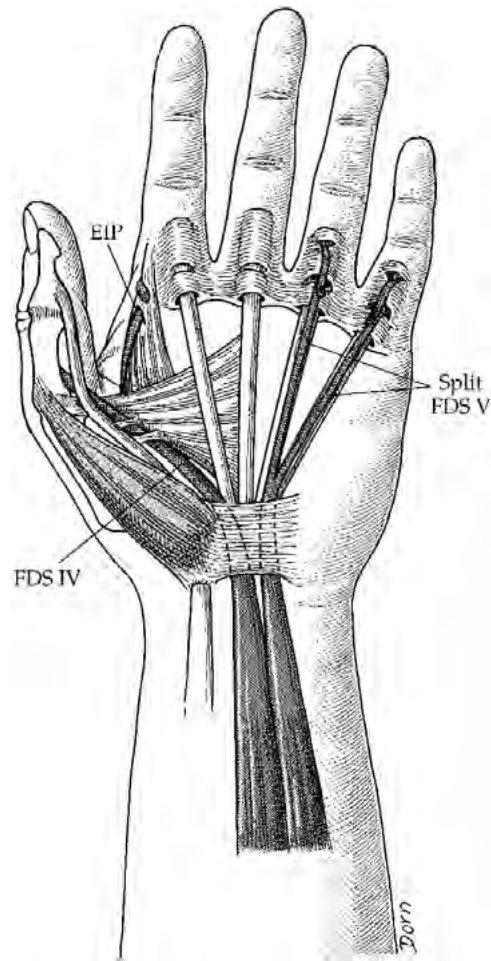


FIGURE 20-19 Tendon transfer plan for low ulnar palsy. The FDS left in the carpal tunnel is passed deep to the digital nerves to restore thumb adduction power. The line of pull is obviously not ideal, but the transfer works well because of the great power of the FDS. There is no satisfactory pulley or "fairlead" more distal. First, dorsal interosseous muscle weakness is corrected by transfer of the EIP to it. Next, the "claw" deformity of the ring and small fingers is corrected by restoring flexion to their respective MP joints by an FDS transfer into the flexor sheaths at the base of the A-2 pulley.

The third alternative, which I prefer, is into the flexor tendon sheath near the proximal end of the A-2 pulley. This procedure is technically simple and provides excellent leverage for MP joint flexion without risk of introducing a new imbalance into the system, such as PIP recurvatum (Fig. 20-20).

Alternative MP Joint Controls. MP arthrodesis to prevent MP finger hyperextension has been mentioned, but there may be tendon transfer alternatives. When a functioning FDS muscle is not available, use of the tendon of a paralyzed FDS muscle as an in vitro graft should be considered, as it

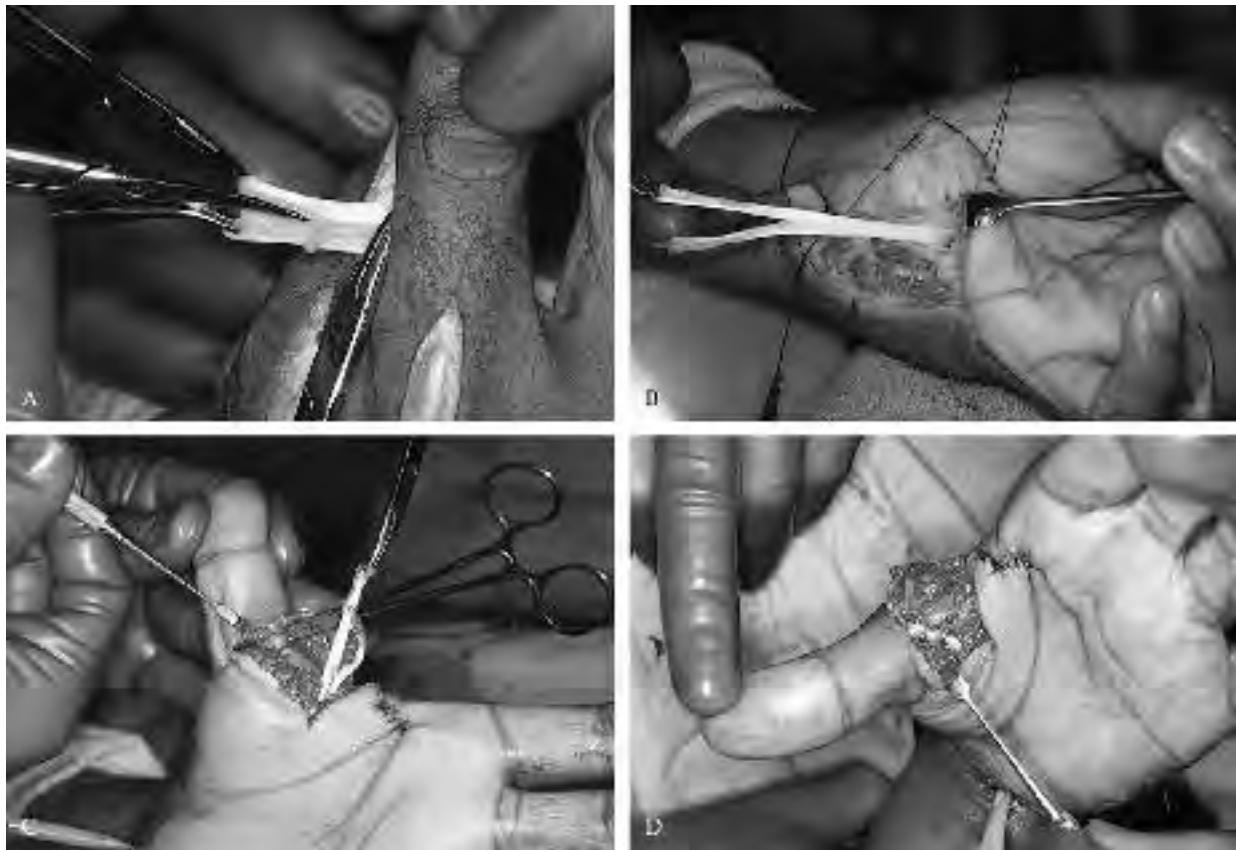


FIGURE 20-20 (A). Clawing of the ring and small fingers is corrected by transfer of an FDS to restore their MP flexion. This prevents hyperextension, while the thumb power of adduction is augmented by another FDS transfer. (B). The two slips of the FDS tendon must be divided to free it from encompassing the flexor digitorum profundus (FDP), or the FDS cannot be withdrawn from the finger. If the PIP joint of the donor finger is hyperextendable, one FDS slip should be left long and attached to the flexor tendon sheath at the proximal phalanx for tenodesis to prevent PIP recurvatum. (C). FDS ready for transfer. In the absence of a good alternative, the FDS to augment thumb adduction is left in the carpal tunnel, whose distal end serves as a “pulley” to change direction toward the thumb. The FDS is passed deep to the branches of the median nerve so as not to compress them. (D). Hand balance is restored by the tendon transfers.

results in fewer adhesions than other grafts carried through abnormal subcutaneous routes. Power can be provided by transfer of the brachioradialis (BR) to the proximal end of the FDS tendon in the forearm (see treatment of tetraplegia or some other available muscle selected according to circumstances).

A lasting and effective static tenodesis against MP hyperextension may be possible with a tendon attached to the flexor sheath distally and proximally either to the transverse component of the palmar fascia or to the distal margin of the transverse carpal ligament. I have had no success with an active tenodesis constructed by carrying a tendon graft between the metacarpals and dorsally across the wrist.

Other efforts have been advocated to prevent MP finger hyperextension. Dermatodesis or excision of skin sufficient to check-rein MP joint extension consistently stretches out and results in failure. A more rational approach is to attach the volar plate of

the MP joints to the neck of the metacarpals. A defect is cut into the bone's cortex, and a flap of the volar plate is drawn through this into the medullary canal for attachment with the MP joint flexed. When forces of extension are low, this has been effective in preventing MP hyperextension and is certainly superior to dermatodesis, but if submitted to strong extension forces, it too stretches out eventually.

Augmentation of Thumb Adduction Power. By far the first choice of transfer to augment thumb adduction is a median innervated FDS muscle (Fig. 20-19). The problem is that there is no fully satisfactory method of getting a line of pull tangential to the long axis of the thumb to adduct it across the palm at right angles to the finger metacarpals. The tendon of all available muscles to restore thumb adduction must pull around a “pulley” (i.e., fairlead) to change its direction. There is no fully satisfactory structure for making this direction change. Using the palmar fascia well distal

to the transverse carpal ligament looks appealing, but feasibility depends on how well the fascia is developed, and even then it tends to stretch out with use. The best compromise is to leave a finger superficial flexor in the carpal tunnel, using the distal edge of the transverse carpal ligament as the pulley. This is not distal enough to be at right angles to the thumb's longitudinal axis, but it is an unyielding structure that does not stretch out. Furthermore, the power of the FDS muscle is so great that despite the mechanical inefficiency of the transfer, it transmits sufficient power for adequate thumb adduction power. The transferred FDS tendon is routed deep to branches of the median nerve and sutured into the intrinsic muscles on the ulnar side of the thumb at the base of the proximal phalanx to flex the MP joint. In taking an FDS tendon from a finger for transfer, it must be recognized that the tendon forms a complete loop around the flexor digitorum profundus (FDP), and this loop has to be cut open for the FDS to be withdrawn from the finger. Also, if the PIP joint of the donor finger is hyperextendable, one slip of the FDS should be cut proximal to the PIP joint and sutured to the tendon sheath, forming a tenodesis to prevent development of a recurvatum deformity. In practice, correction of finger clawing and thumb adduction weakness usually is combined into a single operation (Fig. 20-20). Transfer of the EIP to the first dorsal interosseous muscle insertion can further increase the power of the lateral pinch.

Among other schemes advocated for restoring thumb adduction is muscle lengthened by a tendon graft, carried over the dorsal surface of the hand, down through the paralyzed interosseous muscles between the metacarpals for a change of direction of pull, then across the palm for attachment to the thumb. This is an extensive operation that results in more adhesions, is mechanically less efficient, and offers no advantage over an FDS rerouted from the distal end of the carpal tunnel to the thumb.

HIGH ULNAR PALSIES

A high ulnar nerve lesion also causes clawing of the ring and small fingers, but it results in little additional losses over that of a low ulnar lesion. Specifically, it adds paralysis of the FDP to the small finger and partially to that of the ring finger. This diminishes grasping power. Also, if the nerve lesion is at or proximal to the elbow, paralysis of the FCU results, but this is not noticed if only the ulnar nerve is involved and no treatment is needed. The median innervated FCR provides strong wrist flexion, and the radial innervated ECU provides medial wrist deviation force.

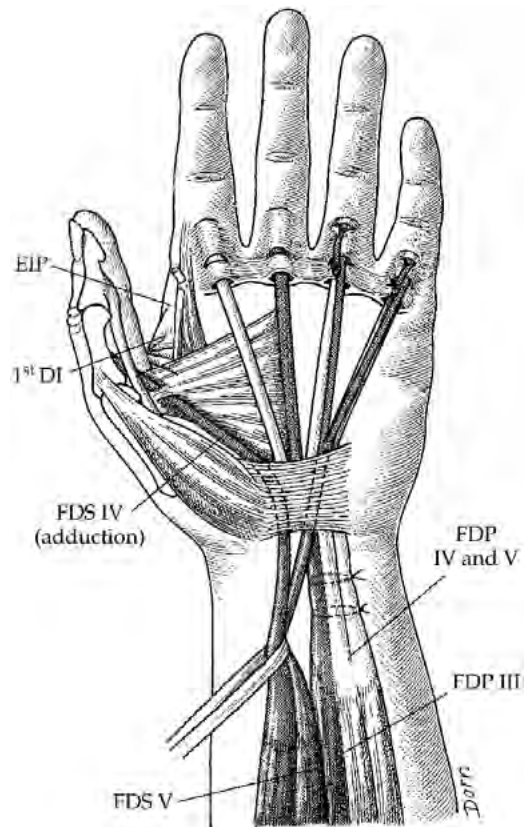


FIGURE 20-21 Typical plan for high ulnar palsy, which differs from a low lesion only by the need to repower the FDP of the ring and small fingers. This is accomplished by suturing them to the median innervated FDP of the middle finger.

Because the FDP of ring and small fingers normally function in conjunction with the median innervated FDP of the middle finger, treatment for ring and small finger FDP paralysis is to transfer their tendons in the forearm to be united side by side into the normal middle finger FDP for an excellent functional restoration (Fig. 20-21).

Median Nerve Palsies

Like the ulnar and radial nerves, there can be either high or low median nerve lesions. Unlike the ulnar nerve, low or distal median nerve lesions cause no major muscle deficits in the hand, and substitutions by tendon transfers are enormously satisfactory. In contrast to this, proximal median nerve palsies result in major muscle impairments, compounding the devastating sensory losses to the prime working surfaces of the hand, which renders precision manipulating impossible.

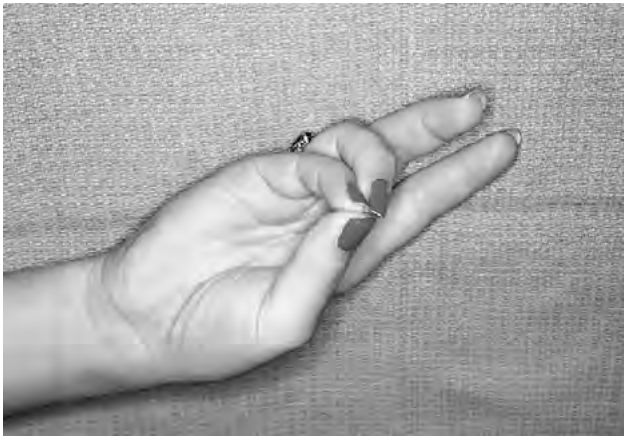


FIGURE 20-22 Good thumb opposition from ulnar innervation of the superficial head of the flexor pollicis brevis (FPB). The patient's median nerve had been severed at the elbow level.

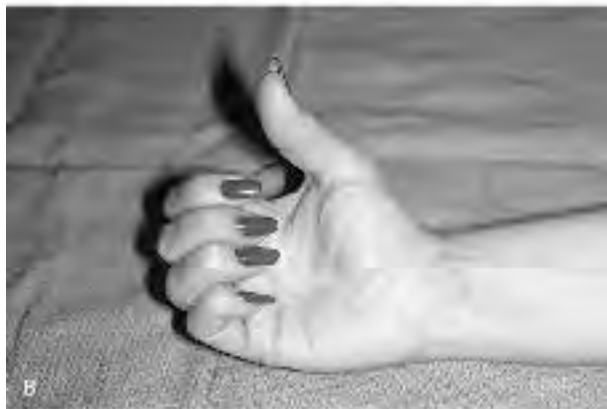
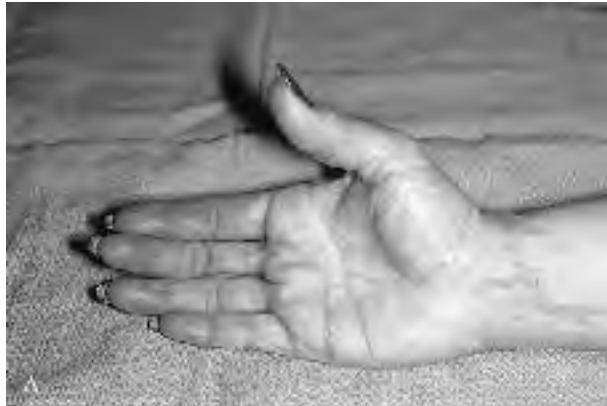
FIGURE 20-23 (A–B). Extended fingers without interosseous muscles to initiate flexion at the MP joints will roll up from their tips into the palm without opposing the thumb pad at any point. For good pulp-to-pulp pinch, finger flexion must be initiated principally at the MP joints. Therefore, if a good flexion arc cannot be restored to the fingers, a thumb opponensplasty is ludicrous.

LOW MEDIAN PALSIES

With low median nerve palsies, the functionally significant power loss is to the thenar positioning muscles of the thumb, the opponens group, of which the vector force is along the abductor pollicis brevis (APB) muscle. When there is overlap of ulnar innervation into the superficial head of the FPB, a low median paralysis can easily be overlooked. Palpation of the shaft of the first metacarpal will reveal no muscle tissues on it, as the opponens pollicis atrophies. Because of ulnar nerve overlap into the superficial head of the FPB muscle, there is about a 35% probability that the thumb's impairment of opposition will not be found to be troublesome (Fig. 20-22), and therefore no treatment will be required. In the past transfers to restore muscle function were considered unwarranted when skin sensibility in the median nerve's distribution was diminished. This simply is not true. Although normal skin sensibility is always desirable, there are many individual factors to be considered. In general, the more severe the losses, the more useful will be even small improvements. The problems actually being experienced by each individual need to be accurately and realistically considered in formulating recommendations. Paralysis of the lumbrical muscles of the index and middle fingers occurs, but this is not noticed because their function is covered by the ulnar innervated interosseous muscles.

With combined median–ulnar paralysis, all fingers initiate flexion at the DIP joints, followed by the PIP joints, and lastly by the MP joints. Fingers that do this “roll up” from distal toward the palm, with their pads never presenting opposite the thumb positioned in palmar abduction (Fig. 20-23). Though normally a coordinated motion, finger flexion needs to be



FIGURE 20-24 Patients without a good finger flexion–extension arc should be provided with a strong “key” pinch, in which the thumb adducts against the side of the index finger, which serves as a passive anvil.

initiated at the MP joints, as they make the greatest contribution to the normal flexion arc (see Chapter 2, Fig. 2–10). If a good finger arc of flexion cannot be restored, opponensplasty is contraindicated. Instead, the thumb should be allowed to work against the side of the fully flexed index finger, which serves as an “anvil” for lateral or “key” pinch (Fig. 20–24).

When augmentation of thumb opposition is needed, several possibilities have proven to be satisfactory. The first principle of successful opponens transfers is that the line of pull be along the vector force of the three muscles of thumb opposition, namely, the line of pull of the APB, which is directly toward the pisiform. The second principle to be observed is to have a stable MP thumb joint. If the joint tends to hyperextend, efforts should be made to stabilize it. Usually this is by splitting the end of the tendon being transferred and using a dual insertion. One slip is placed into the tissues at the first metacarpal head, and the other with slightly more tension is inserted into the base of the proximal phalanx or carried over the dorsum of the thumb to be sutured into the collateral ligament on the radial side of its MP joint. Results are not always predictable, and an arthrodesis of the MP joint may be required. The third principle is to have extension of the thumb’s IP joint so there will be pulp-to-pulp, rather than tip-to-tip, pinch with the opposing fingers. The last principle, and the one most difficult to achieve, is to get maximum thumb pronation for flat pulp-to-pulp contact with the finger pads.

The method most often employed to restore thumb opposition is use of a ring or middle finger FDS tendon transferred by rerouting around the FCU just proximal to the pisiform, which gives it the correct line of pull. From there the tendon is carried subcutaneously out the thenar eminence over the paralyzed APB (Fig. 20–25). The transfer must be carried superficial to the ulnar nerve and artery as it passes under and around to the anterior surface of the FCU so as not to compress the ulnar nerve and artery (Fig. 20–26). Alternatively, a superficial flexor tendon with its peritendon carefully preserved can be brought through a window cut in the proximal transverse carpal ligament and then along the APB. Although the direction of pull is good, this route has an increased risk of restricting adhesions.

Generally, with a stable MP joint, I carry the tendon dorsally over the MP joint, through the EPL distal to the MP joint, to extend the terminal phalanx, then suture its end into the collateral ligaments of the radial side of the MP joint at the base of the proximal phalanx to favor thumb pronation.

Motor units other than an FDS may be used to restore thumb opposition. Among these is the independently functioning EIP (Fig. 20–27), another

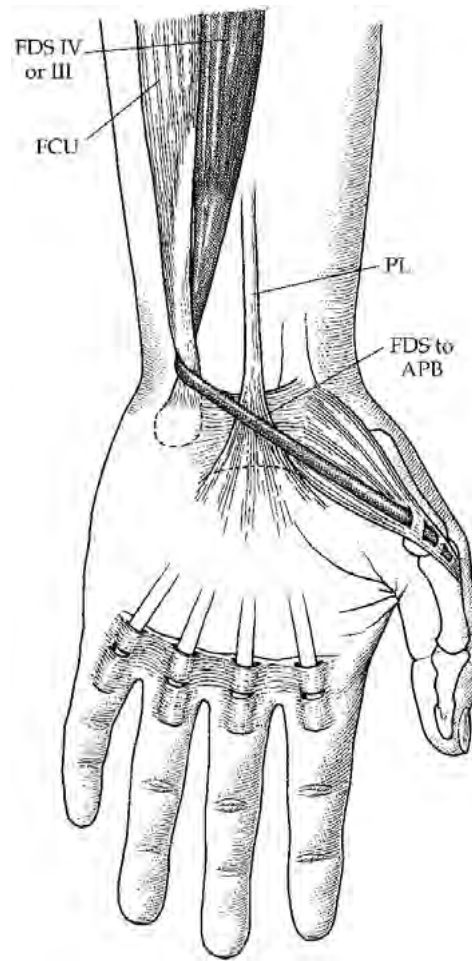


FIGURE 20–25 There are many schemes for restoration of thumb opposition, but among the most satisfactory is a ring or middle finger FDS tendon carried between the ulnar artery and the FCU tendon at the pisiform, then subcutaneously out the thenar eminence along the route of the paralyzed abductor pollicis brevis (APB).

example of how synergism is only a secondary consideration in the selection of a muscle for transfer. The EIP usually is routed subcutaneously around the ulnar side of the wrist and then out the thenar eminence to the thumb’s MP joint (Fig. 20–28). The EIP muscle can be brought through a large opening in the interosseous membrane, which requires less dissection and results in a near-perfect line of pull. There is a risk of troublesome adhesions, however, even when the muscle proper, rather than just its tendon, is brought through a large window created in the membrane.

The ECRL is an excellent muscle for transfers, being powerful and functionally independent. It can be used for a thumb opponensplasty, but its length has to be extended with a tendon graft (Fig. 20–29). It is a very large tendon, so the graft may be obtained by splitting it and using half as the tendon graft.



FIGURE 20-26 (A). Example of atrophy and complete opponens palsy with no ulnar nerve overlap into the deep head of the FPB treated by FDS transfer. (B). The right median palsy precludes pulp-to-pulp finger-thumb pinch, as illustrated by comparison with the normal hand. (C). The FDS tendon is detached from the ring finger, withdrawn in the forearm, and passed around the FCU for the correct line of pull of an opponensplasty, the vector force of the opponens muscle group. The FDS must be carried around the FDC tendon only, superficial to the ulnar artery and nerve to avoid compression of these structures. (D). One slip of the FDS is woven and sutured into the APB tendon at the thumb's MP joint. Tension is set using the tenodesis effect of passive wrist motion. The other FDS tendon slip is carried dorsally over the EPL and sutured into the insertion of the radial collateral ligament at the base of the proximal phalanx to improve MP flexion and to give pronation. (E). Postoperative results with excellent pulp-to-pulp pinch restored.

For multiple nerve and other complex injuries, the abductor digiti minimi muscle can be mobilized on an intact neurovascular pedicle and transferred into the thenar eminence in the space of the paralyzed APB (Fig. 20-30). The down side of this complex procedure is that it requires very extensive dissections and results in a bulky and unaesthetic mass across the base of the palm (Fig. 20-31). The operation is reserved for special cases requiring an opponensplasty for which simpler solutions are not available.

Restoring Thumb Pronation. I have alluded to the main problem common to all opponensplasties: the difficulty in restoring adequate thumb pronation for a flat pulp-to-pulp pinch. When needed, this can be treated by augmenting one of the basic tendon transfers for opposition with detachment of the insertion of the ulnar innervated deep head of the FPB from the medial side of the first MP joint and transferring it over the FPL sheath, deep to the thumb's neurovascular bundles, to the radial side of the MP joint (Fig. 20-32). Technically, this is a difficult

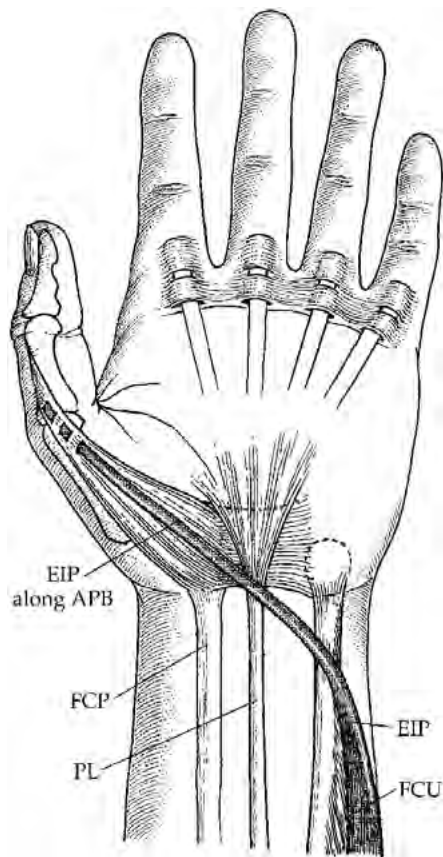


FIGURE 20-27 Plan of opponensplasty using the EIP tendon transfer.

procedure, conducted in a very tight space, with always some risk of neurovascular bundle damage. However, the results can be impressive.

HIGH MEDIAN NERVE PALSIES

High median palsies have, in addition to the loss of thumb opposition, loss of flexion of DIP joints of the index and middle fingers and IP joint of the thumb. With normal radial and ulnar nerve functions and muscles, many plans of substitution for median nerve palsy exist. Interphalangeal flexion of the index and middle fingers that have lost both their FDS and FDP can be restored by suturing their FDP tendons side to side into the profundus tendons of the ring and small fingers. This can be combined with various opponensplasties, such as with the ECRL or ECU lengthened with a tendon graft and the EIP used to restore independent FPL function (Fig. 20-33). Other workable schemes can be planned according to individual circumstances.

For a functionally independent flexor of the thumb's IP joint, the EIP is the best choice, far better than the BR. It is anatomically well situated for the transfer, which is done in the forearm. Though

normally an antagonist to digital flexion, its complete functional independence allows it to substitute perfectly for the FPL. The EIP tendon and muscle are carried through a large window cut in the interosseous membrane and sutured into the FPL in the distal forearm, which results in a direct line of pull.

The restoration of thumb opposition, as in a low nerve palsy, results in a force pulling toward the ulna, which aids forearm pronation. Only rarely is greater power of forearm pronation needed. If it is needed, it can be provided with the ECU withdrawn from its fibrous sheath in the midforearm, then rerouted anteriorly across the forearm and attached to the radius dorsally. An alternative is to transfer the insertion of the biceps tendon from the medial to the lateral side of the radius to reduce its powerful force of supination while augmenting pronation.

Tendon Transfers for Combined Nerve Palsies

If function of any two of the three major nerves to the hand has been lost, reconstruction approaching normal is absolutely precluded, and a simplification of mechanical design is necessary if the available functioning units are to be combined into a useful reconstructive scheme. In cases that include median nerve injuries, the loss of perfect sensibility precludes fine manipulating capability and limits functional recovery even if good muscle rebalancing can be achieved. Primarily only combined median-ulnar lesions will be discussed here, but the principles illustrated can be applied to the other combinations of paralysis according to specific circumstances. It is emphasized that worthwhile improvement for the catastrophic losses from multiple nerve injuries may be possible, but only with major simplification of the mechanical design and specific, limited goals.

Combined Median-Ulnar Palsies

If reconstruction is undertaken for combined median and ulnar paralysis, the need for thumb opposition should be considered only if restoration of a reasonable flexion-extension arc for the fingers can be accomplished. This in turn depends on restoration of interosseous muscle function, which normally initiates finger flexion at their MP joints. Otherwise the repowered FDP tendons will initiate flexion at the DIP joints, causing the fingers to roll up from their tips into the palm. Their pads never approach that of a thumb standing in palmar abduction after opponensplasty (see Fig. 20-23). Unlike an isolated ulnar palsy, with which lumbricals remain to flex the index and middle finger MP joints, with combined median-ulnar palsy, flexion of the MP joints of all four fingers needs restoration.

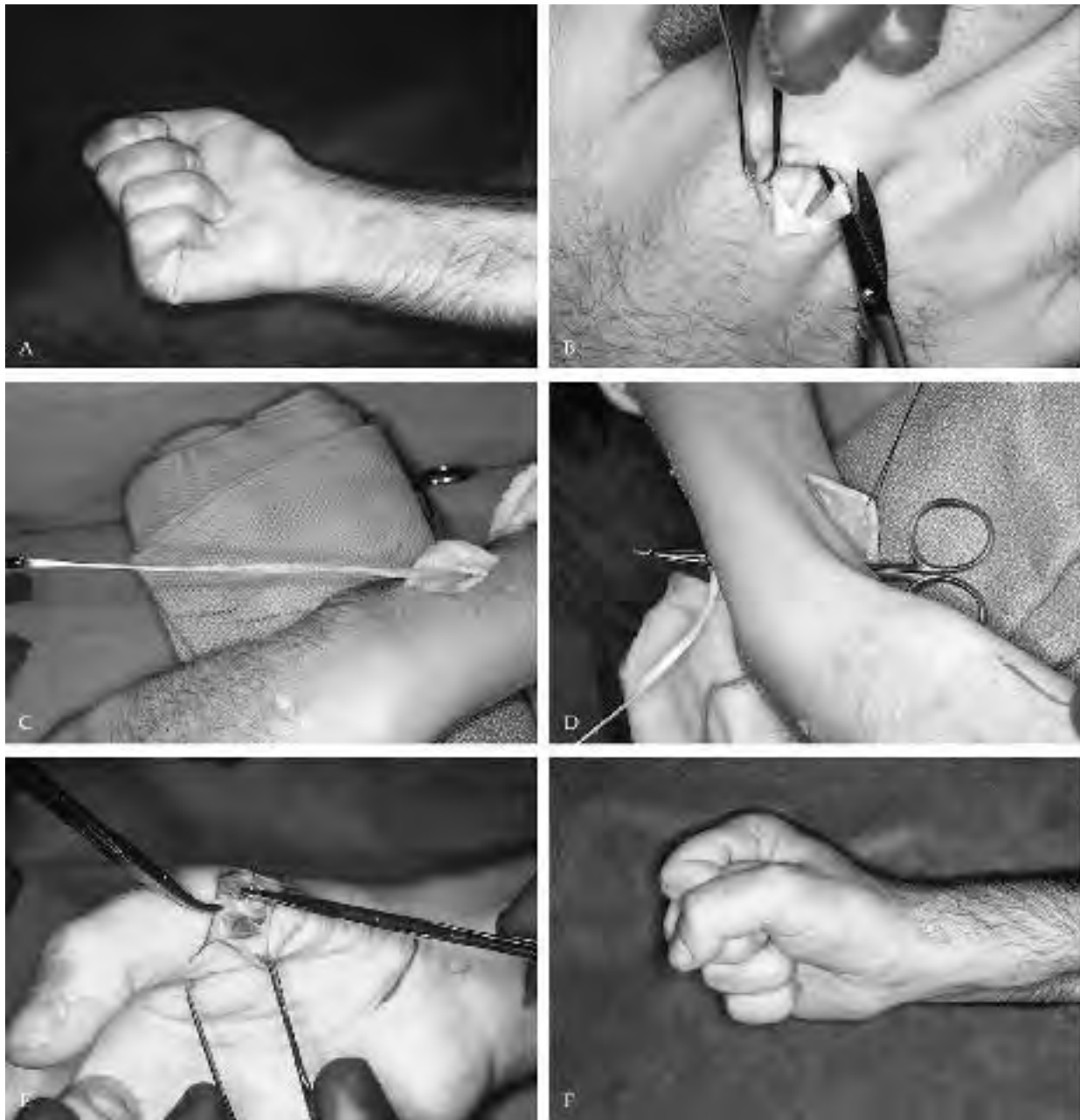


FIGURE 20-28 (A). Complete opponens palsy loss with muscle atrophy. (B). Severing the EIP, which lies to the medial side and deep to the EDC. (C). EIP withdrawn into the distal forearm. (D). EIP muscle rather than its tendon is passed through a large fenestration through the interosseous membrane from the fourth extensor compartment to the volar forearm. (E). The EIP tendon transfer is carried subcutaneously over the paralyzed APB muscle. The most favored distal insertion is weaving into the APB insertion. (F). Postoperative results.

For low median-ular lesions, the best choice for tendon transfers is one or two of the large digital superficial flexors, but a variety of schemes can be useful, depending on what is functional and available. For this reason, it is important to repair, when possible, the superficial digital flexor tendons with classic deep anterior wrist wounds. For large, powerful male patients, the FDS of the middle finger alone

usually is large enough to be split into four slips, with one being used for each finger to restore MP flexion. As with an ulnar palsy, distal attachment to the fingers to restore MP flexion is best achieved by suturing into the flexor tendon sheath at the proximal part of the A-2 pulleys, rather than into bone or the lateral bands. The exception is palsy with PIP joint flexion contractures, for which insertion into the

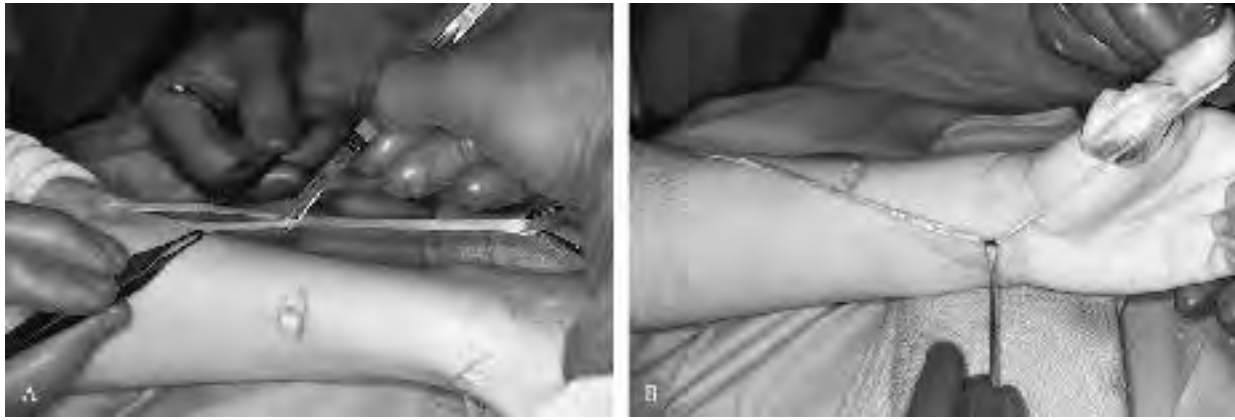

FIGURE 20-29 The extensor carpi radialis longus (ECRL) can be split, with half of it used as a tendon graft to lengthen the ECRL. This makes for an excellent opponens transfer. (B). Plan of routing the tendon graft lengthened ECRL around the FCU and then to the thumb's MP joint for insertion.

lateral bands is preferable, as there is no risk of creating a PIP recurvatum deformity.

In combined median–ulnar palsies, the thumb has lost the function of both its median innervated positioning group of thenar muscles (opponens pollicis, APB, and superficial head of the FPB) and its ulnar innervated power group (deep head of the FPB, adductor pollicis, and the first dorsal interosseous). A single transfer routed along the vector force resulting from these two groups is theoretically attractive but in practice provides poor power and

control. The scheme involves trying to do too much with too little. However, with low median–ulnar lesions, enough muscle–tendon units usually are available for restoration of both the thumb's opposition and adduction, one for positioning of the thumb (median function) and the other for thumb pinching power (ulnar function). In such cases, simplification by fusion of the thumb's IP1 joint may be considered, especially for a nondominant hand or one with median sensory deficit that precludes small-object manipulations. Several schemes are theoretically good but, if complex, prove to be disappointing in practice. The goal of the surgeon should be to keep the reconstruction simple. It is better to restore a few functions effectively than to try to restore a more functioning unit than available assets make feasible.

The combination of arthrodesis of selected joints with tendon transfers for the functionally most important parts often is the best solution when dealing with combined major nerve losses. For example, with extreme losses, arthrodesis of the thumb's carpometacarpal joint in a very carefully selected projection from the palm can be remarkably functional and allows the few muscles available for transfer to be applied for other needs. If the problems of the thumb and the flexion arc of the fingers have been dealt with successfully, IP finger flexion usually is restored for combined median–ulnar palsies by ECRL transfer to the four FDP tendons as a unit. The thumb's IP joint can be fused, leaving enough functioning muscles to transfer for both opposition and adduction of the thumb. When there is doubt about the power of available units for transfer, arthrodesis of the first carpometacarpal joint with a carefully selected projection from the palm will give more predictable and better results.

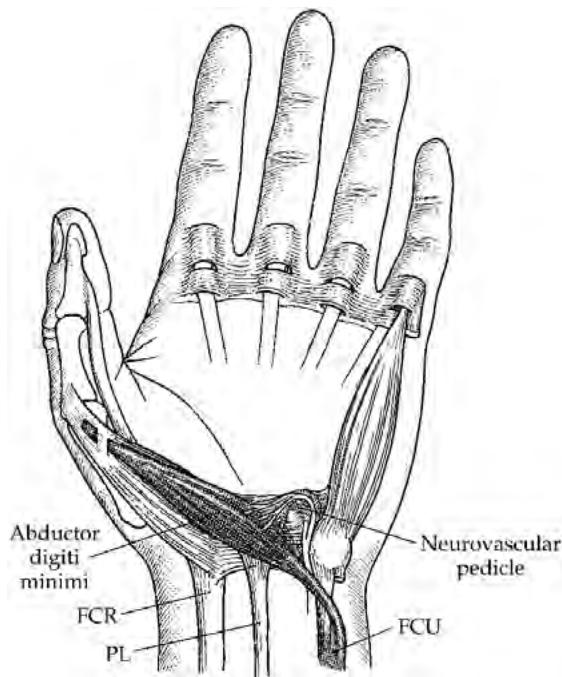


FIGURE 20-30 Plan of abductor digiti minimi neurovascular pedicle opponensplasty.

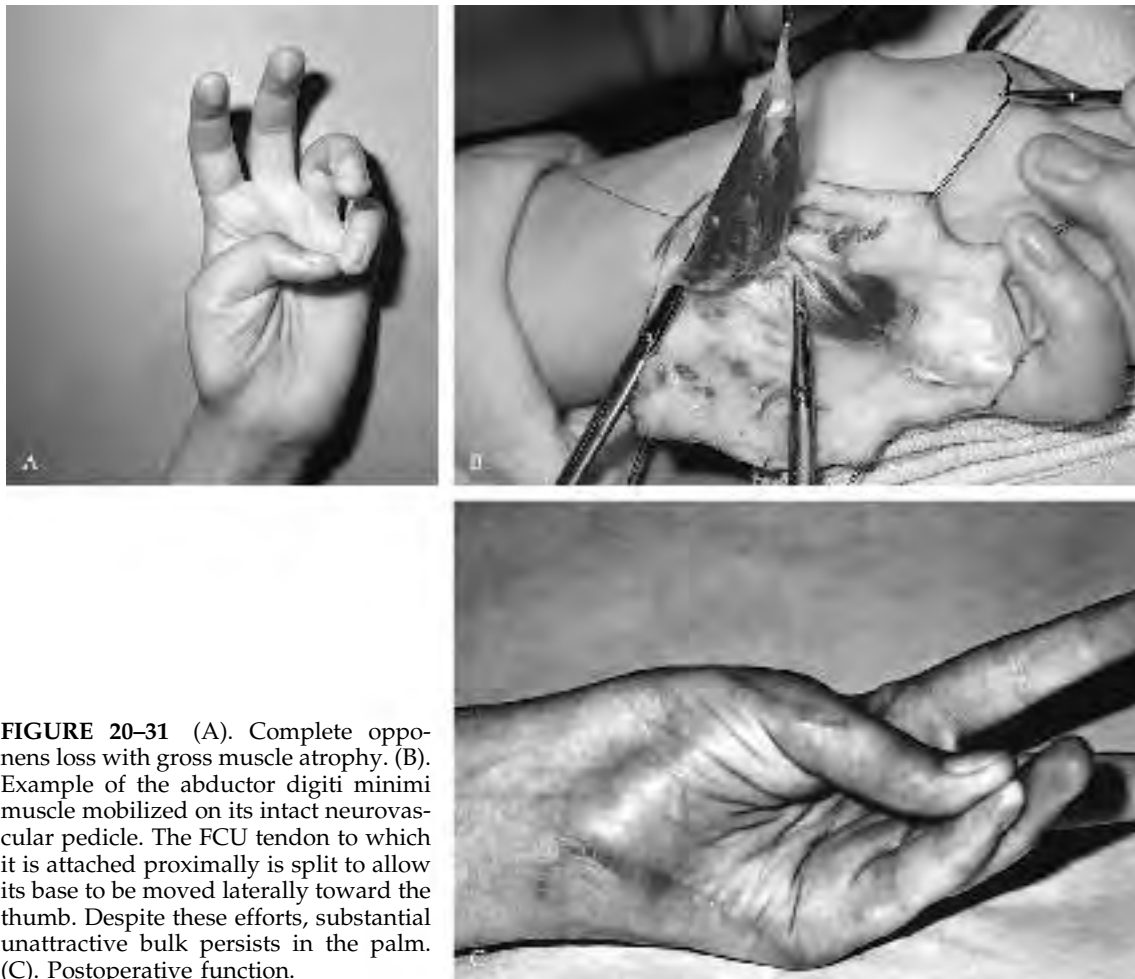

FIGURE 20-31 (A). Complete opponens loss with gross muscle atrophy. (B). Example of the abductor digiti minimi muscle mobilized on its intact neurovascular pedicle. The FCU tendon to which it is attached proximally is split to allow its base to be moved laterally toward the thumb. Despite these efforts, substantial unattractive bulk persists in the palm. (C). Postoperative function.

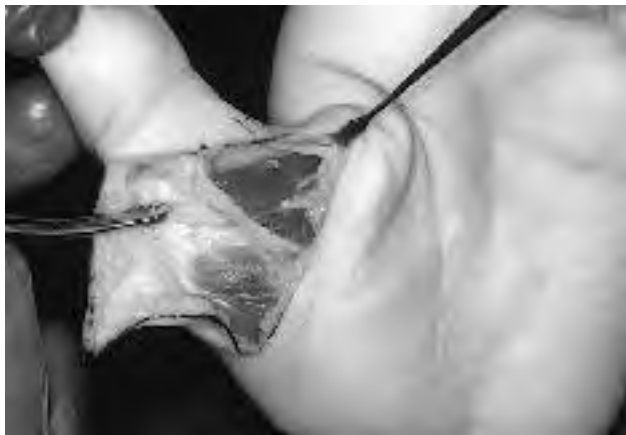

FIGURE 20-32 Thumb pronation for flat pinch is the most difficult challenge of most opponens transfers. The most effective correction is to transfer thenar muscle insertions at the thumb's MP joint from its medial to lateral side. Adductor muscles are detached and passed deep to the neurovascular bundles but over the FPL for reattachment on the radial side to give thumb pronation. The operation is technically difficult but rewarding.

With high median–ulnar nerve palsies, in addition to the losses of combined low median–ulnar lesions, there is complete loss of IP flexion of all fingers, thumb IP flexion, and weak forearm pronation. Generally adding to these devastating disorders is diminished sensibility of all palmar skin, the working surfaces of the hand. The result is a functionally poor hand at best. Several reconstructive schemes may be possible, but mechanical design must be radically simplified. Fusion of the base of the thumb in a carefully chosen projection greatly reduces muscle requirements. The BR can power MP joint flexion transmitted through reattached tendons of paralyzed FDS muscles. IP finger flexion can be restored by transfer of the ECRL to the combined four FDP tendons and perhaps thumb IP flexion provided by transfer of the EIP.

Combined Radial–Median or Radial–Ulnar Palsies

The available muscle units for redistribution are even worse for these combinations than for median–ulnar palsies. There must be radical simplification of design and concentration on one or two prime assisting

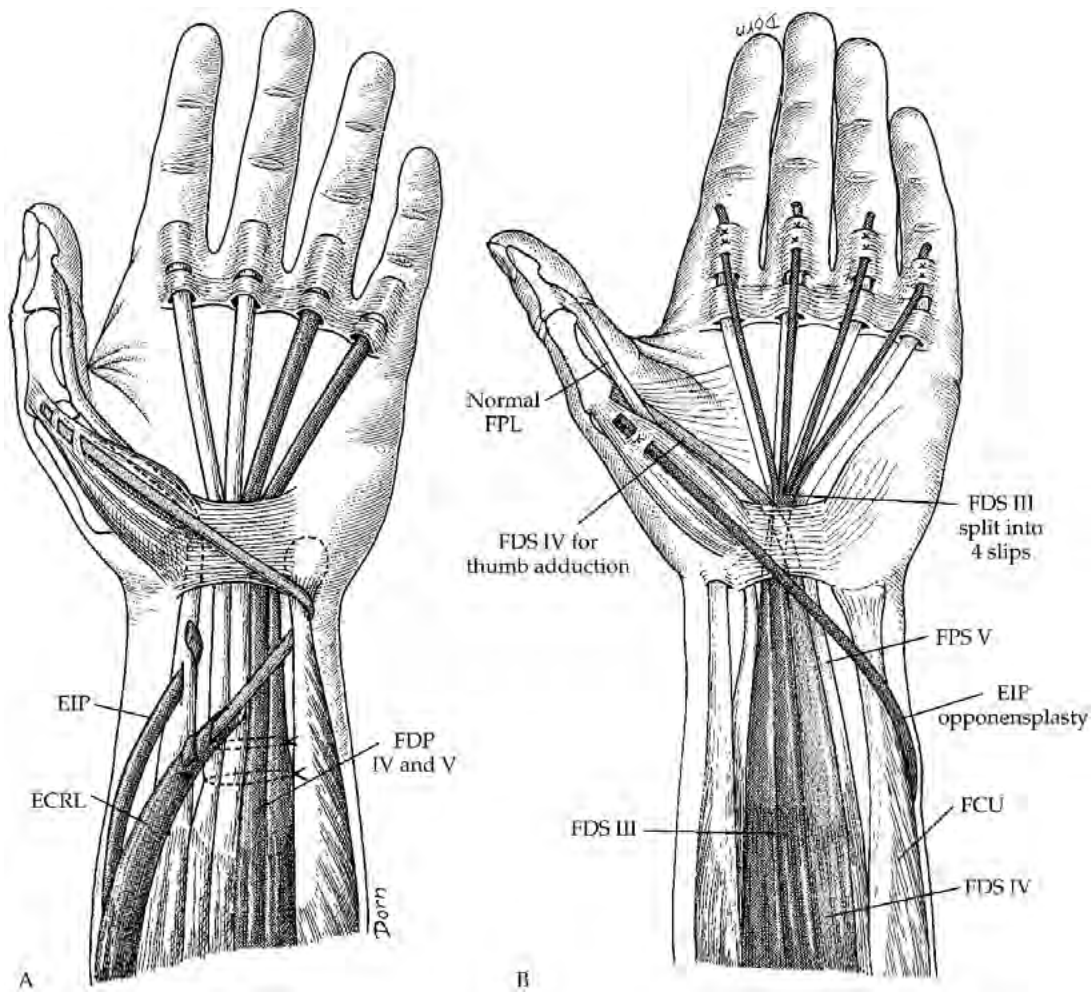


FIGURE 20-33 (A). Example of restoration for high median palsy. (B). Example of tendon transfers for combined low median and ulnar palsies. For combined palsies, the mechanical design needs to be simplified, and usually a combination of arthrodesis and tendon transfers is utilized.

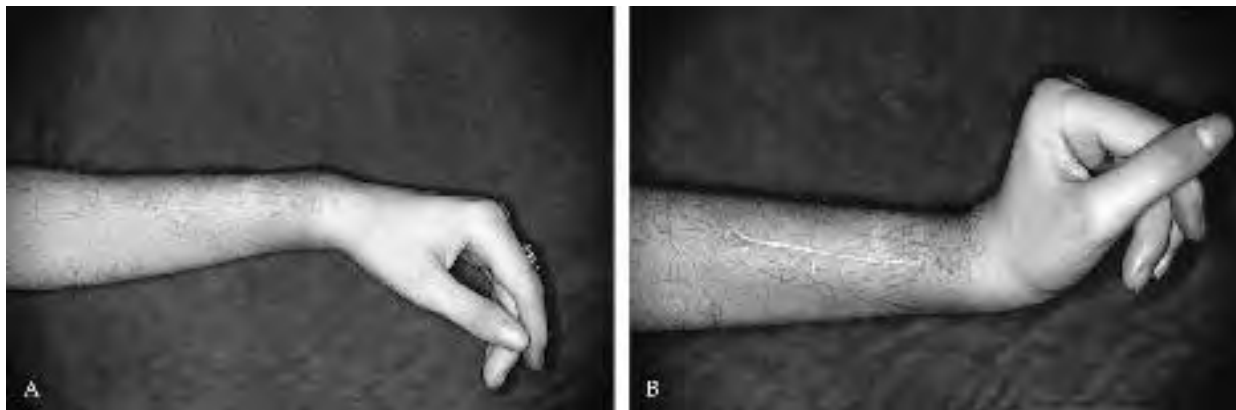


FIGURE 20-34 (A). With C5–C6 spinal cord injuries, if only one muscle is functioning distal to the elbow, it will be the brachioradialis (BR), which in its normal situation has little value. (B). Usefulness of the BR muscle can be significantly enhanced by transferring it into the prime wrist extensor, the ECRB, to restore active wrist extension.

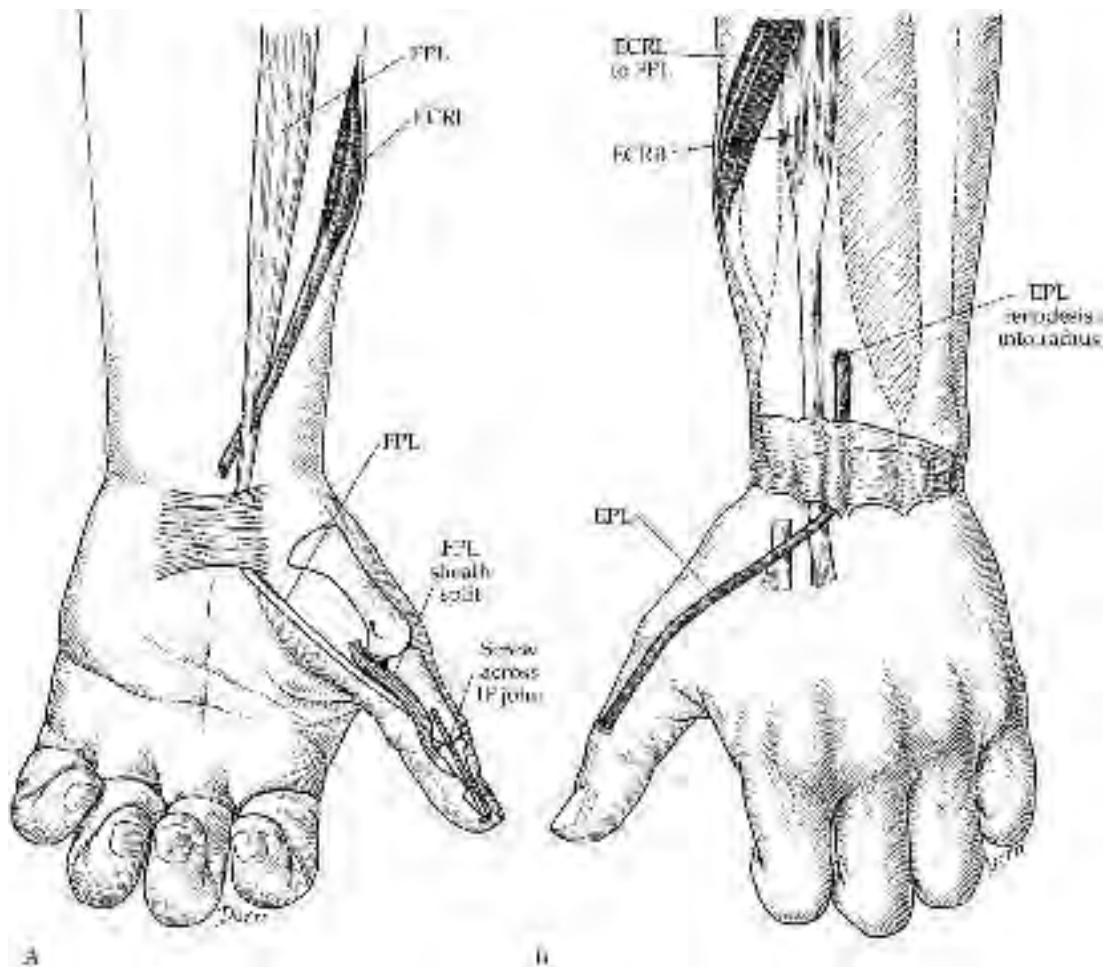


FIGURE 20-35 (A). Example of the Moberg lateral pinch reconstruction with the thumb adducting against the side of the immobile index finger. Although the procedure does not make full use of available parts, it requires only one operation and is relatively simple. (B). Gravity flexion of the wrist provides weak thumb extension after tenodesis of the EPL to the radius.

functions only. The key is to keep it simple and not try to do too much with too little.

Hand Reconstruction for Paralysis Due to Spinal Cord Injuries

The highest level of spinal cord injury for which impressive reconstruction is possible is C5–C6. In lower cord lesions, hands have active digital extension, as in combined median and ulnar nerve palsies. The important factor is the exact level of the spinal cord injury, which is a clinical determination and may vary considerably from that of vertebral fractures radiographically demonstrated. Patients with C5–C6 spinal cord injuries have shoulder control and powerful elbow flexion from their biceps (which also provides forearm supination), but no triceps function to stabilize the elbow. With the C5–C6 level of spinal cord injury, the patient will have four functioning muscles distal to the elbow: the brachioradialis, the

extensor carpi radialis longus, the extensor carpi radialis brevis, and a pronator teres. If wrist extension is weak, the ECRB will not be functioning well, and to take the ECRB for transfer would be a disaster. Wrist fusion is the last thing that should be considered for severely impaired patients. Skin sensibility in the radial and median nerve distributions will be good, whereas that of the ulnar area is lost or of only a poor protective level.

When the spinal cord lesion is cephalad to the C5–C6 level, there is so little with which to work that only the most elementary helping limb can be anticipated. When only a single forearm muscle is functioning distal to the elbow, it will be the brachioradialis. The BR can be put to better use by transferring it into the ECRB to provide active wrist extension (Fig. 20-34). With this, weak adduction and extension of the thumb can be provided by tenodesis. The BR has been called a “dumb muscle,” difficult to integrate into new functions, but when it is the only muscle functioning below the elbow, it provides admirably

for wrist extension. Wrist arthrodesis is absolutely the last thing to be considered for this group of patients.

When spinal cord lesions are lower than the C5–C6 level, the flexor carpi radialis and digital extensors will be functioning. It is easy to restore digital flexion in these cases by tendon transfer because the problem is essentially that of combined median–ulnar muscle paralysis.

Reconstruction for C5–C6 Injuries

Spinal cord injuries at the C5–C6 level are at the most cephalad level for which there is the potential for very dramatic improvement by surgical reconstruction, although there are only four muscles distal to the elbow that are functioning. Obviously a major reduction of mechanical design is essential. There are three basic concepts of reconstruction for these patients: (1) a simple “key” or lateral pinch only; (2) some type of more complex finger–thumb tripod

pattern of prehension; or (3) the extremely efficient system I developed, which combines the thumb–finger pad pinch with the grasping capability. This approach allows for grasping adaptation for various sizes of objects, as well as digital extension and flexion independent of wrist tenodesis. The system also transmits power of the transfers through normal structures so that loss to adhesion is nil. The scheme gets the most from the remaining functional muscles below the elbow.

LATERAL OR KEY PINCH SYSTEM

The restoration of a simple lateral or “key” pinch between the thumb and side of immobile fingers serving as a static “anvil” has been popularized by Moberg (1975). This approach is simple, and the results are predictable, furthermore, only one operation is needed (Fig. 20–35). However, resulting power is weak, the approach to most tasks is unnatural, and

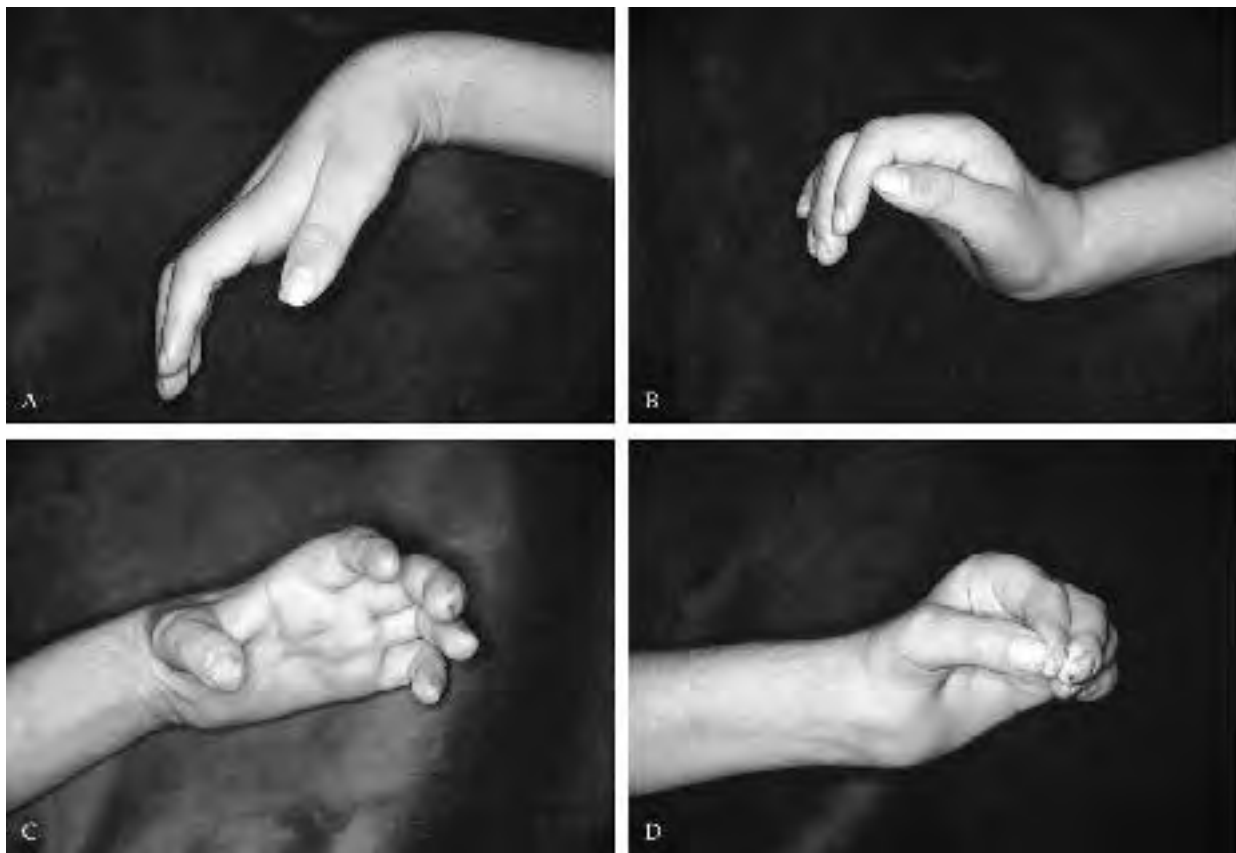


FIGURE 20–36 (A). The “flexor-hinge” procedure was a substantial improvement for C5–C6 tetraplegia, the highest level of cord injury for which dramatic improvement is possible. Essentially, it surgically creates under the skin the system that external tenodesis splints have shown to be worthwhile. IP joints of the fingers and all joints of the thumb are fused. The ECRL is transferred to flex the finger MO joints, which are extended by tenodesis as the wrist is flexed by gravity. (B). Typically, a C5–C6 spinal cord injury patient will have four muscles distal to the elbow functioning (BR, PT, ECRL, and ECRB). If wrist extension is weak, the ECRB will not function effectively, making the ECRL unavailable for transfer. (C). Active opening of extensor tenodesis with wrist flexion by gravity. (D). Effective active pulp-to-pulp pinch (ECRL) between the pads of the index and middle fingers with the fully stabilized thumb.

the potential of the available functional units is poorly utilized. This reconstruction stabilizes the IP joint of the thumb either by arthrodesis or more often with only a screw across it. Thumb adduction to the side of the index finger is achieved by transfer of the ECRL into the FPL, whose sheath or pulley is opened at the MP joint level to cause bowstringing of the tendon, which increases its moment arm of force for MP flexion and thumb adduction. Abduction–extension of the thumb to get around objects is provided by tenodesis of the EPL to the radius. The thumb is therefore weak and requires simultaneous wrist flexion for extension. Thus, the position of the hand is moved just to open and close the thumb.

TRIPOD PINCH OF THUMB TO FINGER PADS

The second basic approach to reconstruction for C5–C6 spinal cord injuries is to restore the thumb-to-finger tripod pinch mechanism characteristically employed by a normal hand for precision manipulations. This is feasible because of the good sensibility of the median innervated skin on the working surfaces of the thumb and index and middle fingers. The thumb is fused at all three joints with a carefully chosen projection from the palm to meet the pads of the index and middle fingers. With such small forces, often only a screw is placed to stabilize the IP joint. Finger flexion is only at the MP joints where active flexion for all four fingers is restored by ECRL tendon transfer after fusion of both PIP and DIP joints. If wrist extension is weak, the ECRB is not functioning, and the ECRL must not be taken for transfer. The transfer juncture is in the forearm and can be into either the FDS or the FDP tendons. Power transmis-

sion is through normal channels. Extension usually is provided by tenodesis of the EDC to the radius, and wrist flexion is by the FCR or by gravity. The reconstruction is performed in two stages, the first for the arthrodesis of all joints of the thumb and all IP finger joints. The second stage is a tendon transfer for active flexion of all fingers at their MP joints and tenodesis of the EDC for opening (Fig. 20–36).

This “flexor-hinge” type reconstruction, as advocated by Nickel (1963), replicates under the skin a wrist-driven “flexor tenodesis” external splint that can be used for preoperative evaluation of the procedure by patients. It also can result in a hand capable of finger-to-palm gross grasping, but only of large objects, as there is no interphalangeal mobility. With both IP joints fused, the fingers cannot adapt configurations according to the size of the object to be grasped. Yet impressive improvement can follow this type of reconstruction, and the margins for error are sufficiently great that it is recommended for surgeons without extensive experience with paralytic problems.

Optimal Reconstruction for C5–C6 Tetraplegia

I developed a third basic reconstruction that maximally utilizes the four available muscles of the forearm (BR, ECRL, ECRB, and PT). The results are superb, but it is complex, usually done in three surgical stages, and has little margin for technical errors. With this design scheme, power is transferred through in situ tendons of paralyzed muscle in their normal channels, so power lost due to adhesions or abnormal mechanical mechanisms is nil. The resulting hand, with normal median skin sensibility, is capable of precision pinch with the tips of the thumb and the

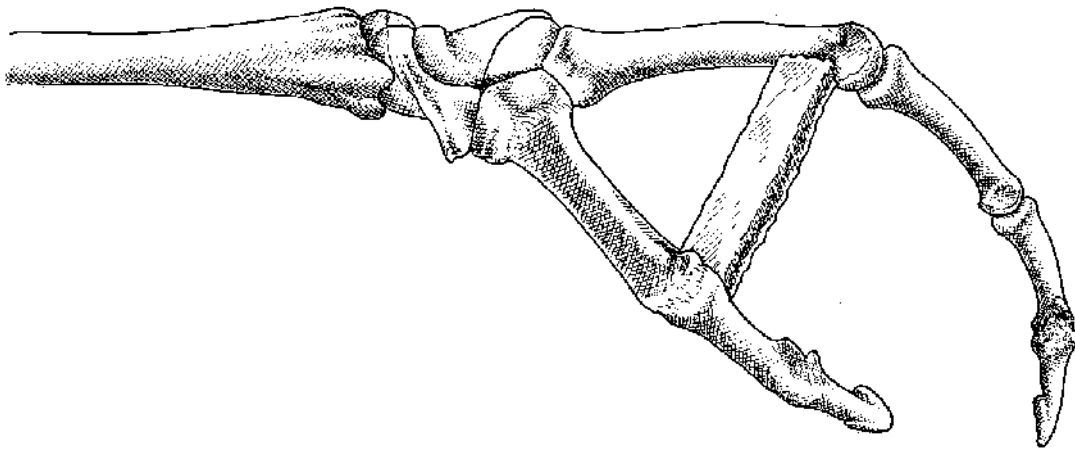


FIGURE 20–37 First stage of my optimal reconstruction procedure for C5–C6 tetraplegia. The finger DIP joints are fused because they contribute so little to the finger flexion arc. All joints of the thumb are fused, and a bone graft is placed between the first and second metacarpal heads to create a strong triangular configuration that will not fracture as the patient places full weight on it for transferring. If a fifth muscle is available for transfer, it can be used to power the FPL, leaving the thumb's IP joint mobile. However, this last step does not improve function and is therefore no longer done.

index and middle fingers. In addition, restoration of a near-normal flexion arc for the fingers provides strong grasping power for objects of all sizes. The capability of independent flexion of either the MP or the PIP joints results in the fingers being able to accommodate objects of almost any size or shape. For grasping large objects, finger flexion will be at the PIP joints, while the MP joints remain in extension. For small objects, the finger flexion is principally at the MP joints to bring the tips of the thumb and fingers together. Both extension and flexion of the fingers are active and fully independent of wrist motion, although that function is preserved and contributes to strategic positioning as well as augmentation of digital power by the tenodesis effect in the manner of a normal hand. There is no reduction of any preoperative capability resulting from the procedure.

In the first stage, arthrodesis for essential skeletal stabilization is done (Fig. 20-37). This includes fusion of all three thumb joints, with a carefully planned projection from the palm for the pad of the thumb to meet the index and middle fingers, flexed at their MP joints while their IP joints are extended. An iliac bone graft is placed between the first and second metacarpals to form a triangular support for the long cantilevered thumb to prevent its fracturing. The distal IP joints of all four fingers are fused in 15 to 20 degrees of flexion, as they contribute so little to the flexion-extension arc of the fingers compared with the PIP joints (see Chapter 2, Fig. 2-10).

The second stage involves restoration of active digital flexion (Fig. 20-38). PIP joint flexion is restored by transfer of the ECRL in the forearm into the four FDP slips that will flex the PIP joints, as the DIP joints

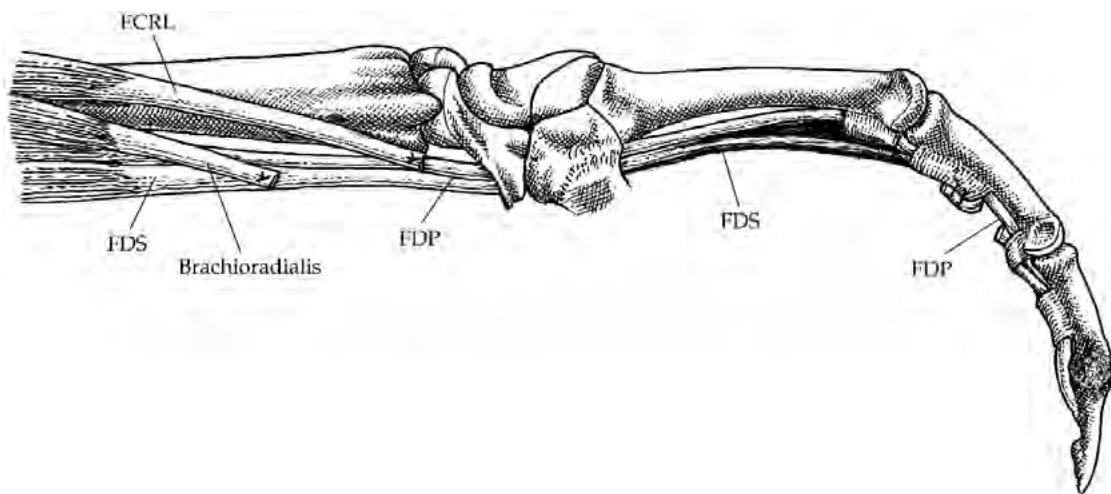


FIGURE 20-38 Details of restoration of active finger flexion. The ECRL is transferred into the four FDPs, which now flex the PIP joint because the DIP joints have been fused. The superficial flexors (FDS) are powered by transfer of the BR to them in the forearm. The FDS's are attached to the flexor tendon sheath at the middle of the proximal phalanges to become MP joint active flexors powered by the BR (see Fig. 20-39).

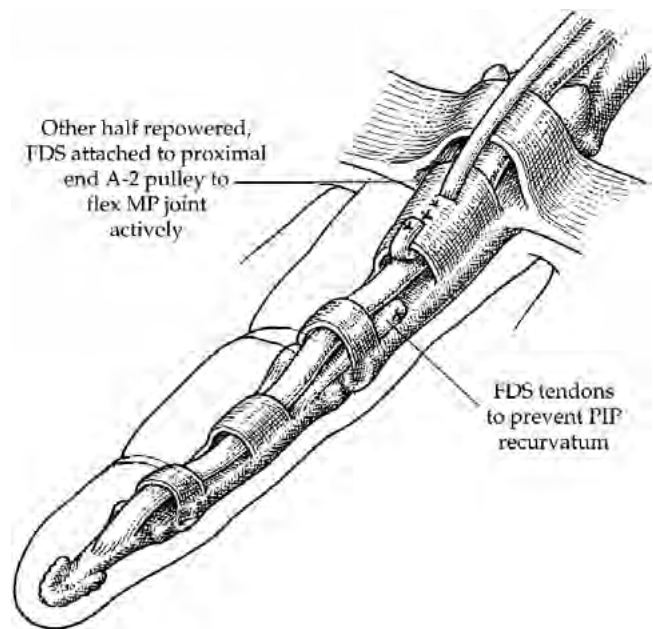


FIGURE 20-39 Distally, the two slips of the FDS tendons are separated. One is left long in each donor finger and sutured into the flexor tendon sheath at the proximal phalanx to prevent PIP recurvatum. The other slip of each FDS tendon is collectively powered by the BR; one is brought through the flexor tendon sheath at the proximal end of the A-2 pulley of each finger and sutured to itself to provide MP flexion. This prevents MP hyperextension, so the subsequently repowered EDC will give PIP extension through the central slips of the extensor system.

have been fused. MP finger joint flexion is provided by the BR transferred into the four FDS tendons, which are left in their normal beds to prevent adhesions. Distally, one slip of the paralyzed FDS is

cut at the MP joint level, then turned back and sutured to itself with check-reining of the PIP joint in 15 degrees of flexion to prevent a PIP recurvatum deformity (the DIP joint is fixed in slight flexion). The other slip of each FDS is cut near its insertion into the middle phalanx, brought out through the flexor tendon sheath at the proximal part of the A-2 annular pulley, and sutured to itself (Fig. 20-39). Thus, the FDS tendons in their normal beds serve as *in vitro* tendon grafts, free of adhesions, for the BR to restore active MP finger flexion and to prevent MP hyperextension.

The third stage of the reconstruction involves restoration of active digital extension and independent wrist movements. This is done by transfer of the PT into the EDC on the dorsal surface of the forearm, just above the normal insertion of the PT into the radius. Because the restored finger flexors block their extension and the biceps muscle relaxes (it is a supinator), the PT pronates the forearm almost normally. For finger extension, the biceps muscle, which is a supinator, blocks pronation of the forearm; the finger flexors relax and are extended by the pull of the PT through its transfer into the EDC. A composite illustration of the completed reconstruction is shown in Figure 20-40.

This reconstruction is complex, but it utilizes the remaining upper limb assets of severely handicapped C5-C6 spinal cord injured patients (Fig. 20-41). In my experience, postoperative power grasp following this type of reconstruction averaged 17.3 lbs, with a range of 15 to 21 lbs. Precision pinch power averages 6.2 lbs.

Restoring Active Elbow Extension

Paralysis of the triceps results in an unstable elbow with no active extension. Restoring active elbow extension and stabilizing the elbow are achievable goals (Fig. 20-42). Because the posterior portion of the deltoid muscle is functional in C5-C6 tetraplegics, it can be lengthened with a strong tendon graft, or several grafts side by side, to substitute for the triceps loss and without impairment of the shoulder. The chief objection to this functionally excellent transfer is that remobilization of elbow flexion must be slow. Initial immobilization is in full elbow extension for about 6 weeks, followed by fitting with an adjustable brace that allows a weekly increase of flexion of only about 5 degrees of flexion.

Postoperative Management for Tendon Transfers

Immediately following tendon transfers, a rigid dressing, usually a plaster cast, is required to immobilize the parts in a position selected to minimize tension and the chance of tendon junctures being disrupted. The dressing for children requires special efforts. The protective position should be used to minimize small joint stiffening, but some compromise often is necessary.

An absolute minimum of 3 weeks of immobilization is required for all tendon transfers; usually a longer period is needed for children. Flexor tendon transfers are immobilized for 3 to 4 weeks, but extensor tendons are immobilized longer, about 5 to 6 weeks.

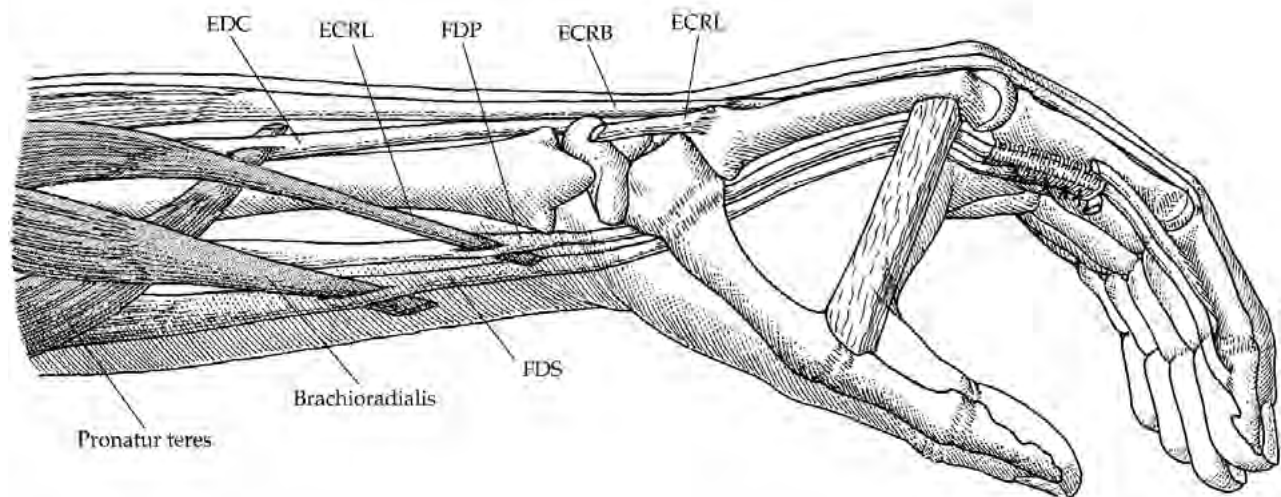


FIGURE 20-40 Composite presentation of the completed reconstruction, including restoration of independent finger extension ability. Note that the insertion of the PT into the EDC is directly over the PT's normal insertion. If the patient wishes to extend the fingers, the biceps (a supinator) will block forearm rotation, the restored flexor antagonist muscles will relax, and the PT will pull through the EDC, thereby extending the fingers. If the patient wishes to pronate the forearm, the biceps will relax, the restored finger flexor system will prevent finger extension, which fixes the point of RT attachment near the normal PT insertion, and the forearm will be pronated.

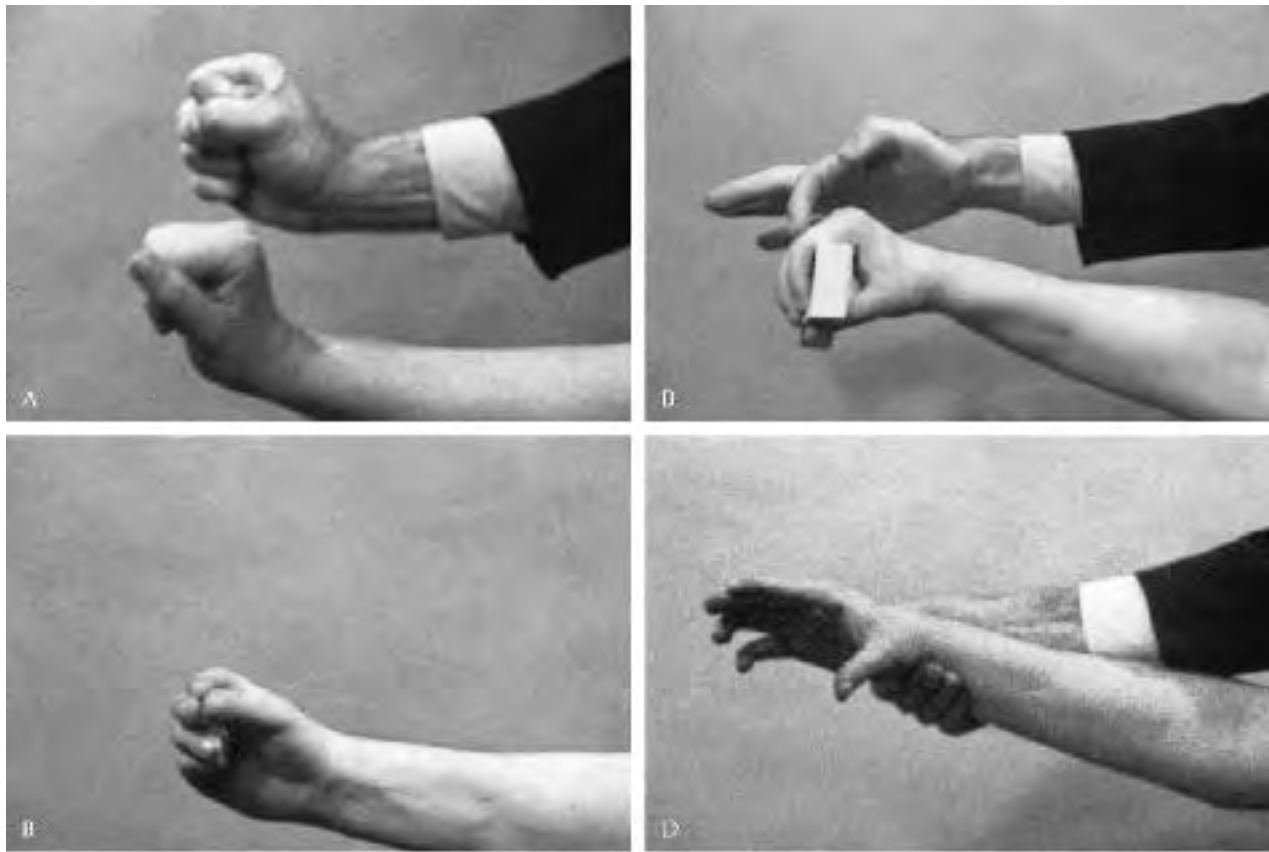


FIGURE 20-41 (A). Preoperative strong wrist extension by the ECRB, but no active finger flexion or extension. Postoperative results of my reconstruction procedure for C3–C6 tetraplegia, with a combination of arthrodesis and tendon transfers in a carefully planned scheme using only the four functioning muscles distal to the elbow. (B). With independent flexion of both the MP and PIP finger joints, the hand can accommodate to any size object. Illustrated is grasping a moderately large object, for which the MP joints are only slightly flexed and the PIP joints are flexed fully. Neither flexion nor extension requires wrist movement for tenodesis. (C). Precision pinch with flat pulp-to-pulp contact between the thumb and the index–middle finger pads. Flexion is entirely at the MP joints for small objects and more at the PIP joints for large objects to accommodate to any size. (D). Full opening of the hand without wrist movement. The space between the thumb and the fingers is determined by the size of the hand. In the large hand illustrated, it was 10.2 cm.

This is not because they heal differently but because they are opposed by powerful flexor antagonists. Completely unrestricted use is not encouraged for any tendon transfer until 8 to 10 weeks postoperatively; posterior deltoid transfer for the triceps will require an even longer period of immobilization.

Reeducation of Transferred Muscles

The difficulty in “reeducating” a transferred muscle is inversely proportional to the usefulness of the new arrangement. Most tendon transfers that have been well considered and skillfully carried out require remarkably little effort, and often formal therapy is not needed for them to quickly function automatically at their new task. This is understandable if one considers how their muscle control system normally functions.

Neurologic Control of Muscles

Control of muscles is essentially an extremely rapid trial-and-error process based on constant monitoring of actions achieved in terms of progress toward desired goals. The cerebral cortex initiates a desired action by calling on muscles previously used for a similar action, but it then constantly modifies the commands and even the muscles selected for action according to its monitoring and interpretation of the progress toward desired goals from sensory and visual feedback surveillance. If the job is not being done well, the cortex will curtail or abolish its initial directives and recruit other muscle combinations until it gets the desired action. This is why fully automatic control is lost if there is any impairment of the sensory feedback systems, and why essentially all control is lost in the rare situation of blindness and loss of skin sensibility. The handwriting of a person with a sensory deficit who is then blindfolded becomes

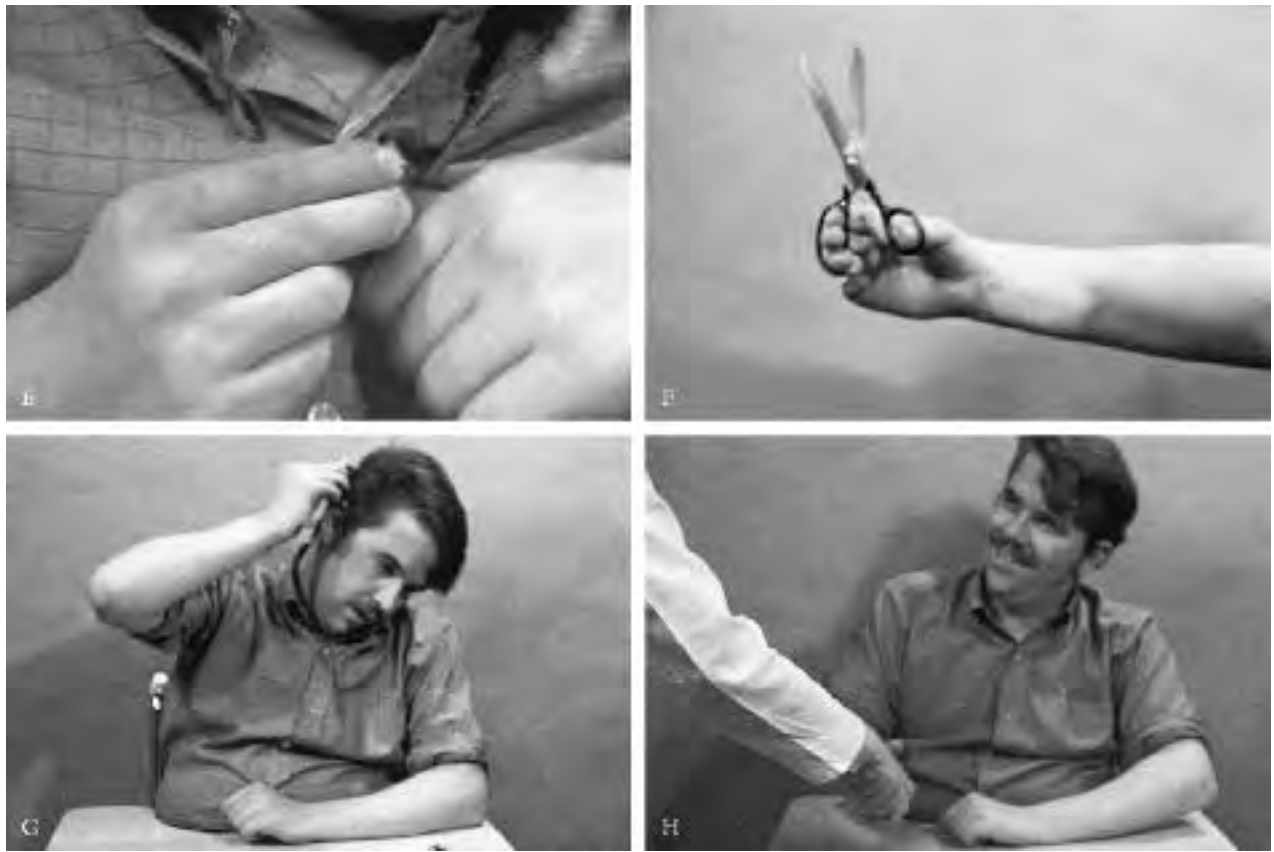

FIGURE 20-41 (E). Closing buttons. (F). Using scissors. (G). This reconstruction was combined with a triceps substitution for control of the elbow using the posterior deltoid, which was lengthened by tendon grafts. (H). The patient's ability to shake hands comfortably is much appreciated.



FIGURE 20-42 (A). Posterior deltoid extended by tendon grafts gives an excellent functional restoration. Example of unrestricted elbow flexion following the transfer. (B). Elbow extension and control following posterior deltoid transfer with tendon grafts and insertion into the triceps tendon.

illegible, as both tactile and visual monitoring links in the muscle control system have been lost.

Muscle reeducation after tendon transfers is basically related to the usefulness of the transfer and not the muscle selected or the formal programs for direct adaptation. The process can be compared to learning a language. The natural “mother” system of associating each sound with a desired result, for example, is infinitely better than a clumsy attempt at word-for-word translation. This is not to belittle the importance of the physical therapist, whose help with breaking inhibitions, dealing with anxieties, remobilizing, and power building can be invaluable for some patients.

SUGGESTED READINGS

- Beasley RW. Principles of tendon transfer. *Orthop Clin North Am.* 1970;1(2):433–438.
- Beasley RW. Tendon transfers for radial nerve palsy. *Orthop Clin North Am.* 1970;1(2):439–445.
- Beasley RW. Surgical treatment of hands for C5–C6 tetraplegia. *Orthop Clin North Am.* 1983;14(4):893–904.
- Beasley RW. Tendon transfer. In: Beasley RW, Thorne CHM, eds. *Grabb and Smith's Plastic Surgery*. Philadelphia: Lippincott-Raven; 1997:939–951.
- Brand PW. Tendon transfers for median and ulnar nerve paralysis. *Orthop Clin North Am.* 1970;1(2):447–454.
- Brand PW. Tendon transfer reconstruction for radial, ulnar, median, and combination paralysis: principles and techniques. In: McCarthy JG, ed. *Plastic Surgery*. Philadelphia: WB Saunders; 1990:4923.
- Burnell S. *Surgery of the Hand*. Philadelphia: JB Lippincott; 1944.
- Duchenne GBA. *Physiologie des mouvements démontrée à l'aide de l'expérimentation électrique et de l'observation clinique, et applicable à l'étude des paralysies et des déformations*. Paris: Ballier; 1867.
- Littler JW. Tendon transfers and arthrodesis in combined median and ulnar nerve palsy. *J Bone Joint Surg.* 1949;31A:225.
- Littler JW. Restoration of power and stability in the partially paralyzed hand. In: Converse JM, ed. *Reconstructive Plastic Surgery*. Philadelphia: WB Saunders; 1967:1674.
- Littler JW. Restoration of power and stability to the partially paralyzed hand. In: Converse JM, ed. *Reconstructive Plastic Surgery*. 2nd ed. Philadelphia: WB Saunders; 1979:3266.
- Littler JW, et al. Opposition of the thumb and its restoration by abductor digiti quinti transfer. *J Bone Joint Surg.* 1963;45A:1389.
- Manktelow RT, McKee NH. Free muscle transplantation to provide active finger flexion. *J Hand Surg [Am]*. 1978;3(5):416–426.
- Moberg E. Surgical treatment for absent single-hand grip and elbow extension in quadriplegia: principles and preliminary experience. *J Bone Joint Surg [Am]*. 1975;57(2):196–206.
- Nickel V. Development of useful function in severely paralyzed hands. *J Bone Joint Surg.* 1963;45A:933.
- Pomerance J. Management of spastic disorders of the hand. In: Aston SJ, Beasley RW, Thorne CHM, eds. *Grabb and Smith's Plastic Surgery*. Philadelphia: Lippincott-Raven; 1997:953.
- White W. Restoration of function and balance of the hand and wrist by tendon transfers. *Surg Clin North Am.* 1960;40:427.